

Comparison of upper pharyngeal airway space in Class II and Class III malocclusion cases

Saba Yousuf Shaikh^a, Arshad Mahmood Malik^b, Owais Khalid^c, Madiha Mahnoor^d

Abstract

Introduction: Evaluation of pharyngeal airway has an important role in diagnosis and treatment planning in patients with obstructive sleep apnea and dentofacial deformity. The purpose of this study was to evaluate the widths of the upper pharyngeal airways in patients with skeletal Class II and Class III malocclusions.

Material and Methods: The sample comprised of sixty subjects divided into 2 groups (30 Class II and Class III respectively). The upper pharyngeal airway was assessed according to McNamara's airways analysis. Independent t-test was used to compare upper airway space in both skeletal classes.

Results: Independent t-test showed a statistically significant difference ($p < 0.05$) in upper airway space between two groups showing Class II cases to have narrower upper airway space as compared to Class III cases.

Conclusions: Subjects with Class II skeletal malocclusions have significantly narrower upper pharyngeal airways than those with Class III malocclusions.

Keywords: Pharyngeal airway spaces; vertical growth pattern; obstructive sleep apnea.

Introduction

For many years cephalometric radiographs have been used to evaluate facial growth and development.^{1,2} Cephalometry enables analysis of skeletal and dental anomalies as well as soft tissue structures and form.^{3,4} Many studies have assessed the anatomic details of the upper airway with more sophisticated and expensive techniques including computed tomography, fluoroscopy, acoustic reflection, fiberoptic pharyngoscopy and magnetic resonance imaging. Cephalometry is, however, less expensive and more useful. But the proper analysis of cephalograms rely on accurate identification and location of accurately defined anatomical and constructed landmarks on human

cephalograms.^{3, 5, 6, 7}

Normal airway plays an important role in the normal growth of the craniofacial structures.^{3, 4, 8} Analysis of the significance of variations in the growth and function of the nasal cavities, the nasopharynx, and the oropharynx is dependent on an understanding of the normal growth of the skull. Significant relationships between the pharyngeal structures and both dentofacial and craniofacial structures have been reported.^{3, 4} The close relationship between the pharynx dentofacial and craniofacial structures determines their mutual interaction.³

Normal upper airway space is 15-20 mm while lower airway space is 11-14 mm.³ This has been observed that the size of the Pharyngeal Air Space (PAS) clearly differs among subjects with a normal mandible, mandibular retrognathism and mandibular prognathism.^{9, 10} The position of the mandible (anteroposteriorly) most likely affects the position of the base of the tongue because by the genioglossus muscle the tongue is connected to the inner surface of the anterior mandible. Evaluation of the Pharyngeal Air Space (PAS) has a very important role in diagnosis and treatment planning in patients with dentoskeletal deformity and in patients

^a Corresponding author, BDS, PG trainee, Islamic International Dental Hospital, Riphah International University, Islamabad. Email: dr.saba_omer@hotmail.com

^bBDS, MDS, Associate Professor, Dental Section, Punjab Medical College, Faisalabad.

^cBDS, FCPS, Morth, FFD, Assistant Professor, Islamic International Dental Hospital, Riphah International University Islamabad.

^dBDS, PG trainee, Islamic International Dental Hospital, Riphah International University Islamabad.

with the complaint of Obstructive Sleep Apnea.^{12, 13} As Pharyngeal Air Space diameter is different in subjects with different malocclusions and narrow PAS has been associated with breathing difficulties such as obstructive sleep apnea (OSA).^{3, 9} This study aims to evaluate Pharyngeal Air Space in patients presenting to orthodontics department of Islamic international dental hospital with dentoskeletal deformity for orthodontic treatment.

Material and Methods:

Pretreatment standard lateral cephalograms of 60 patients recorded on Rotograph Plus, were taken from the existing records of orthodontics department, Islamic International Dental Hospital, a tertiary health care facility. Informed written consent was obtained from all the participants. Only skeletal Class II and Class III patients of either gender between the ages of 12-28 years (Table I) (Figure 1), with no previous history of orthodontic treatment were selected for the study. Patients who had any pharyngeal pathology, allergies or undergone adenoidectomy or any other nasopharyngeal surgery were excluded from the study. Also patients with generalized growth disorders were excluded from the study.

Table I: Mean age of patients

Mean Age of Patients					
MAL	N	Mini mum	Maxi mum	Mean	Std. Deviation
C III	30	13.00	26.00	18.0667	3.51287
C II	30	12.00	28.00	16.9667	4.11459
Total	60	12.00	28.00	17.5167	3.83336

Table II: Means and standard deviations of Class III malocclusion

Descriptive Statistics					
GROUP	N	Mini mum	Maxi mum	Mean	Std. Deviation
CIII	30	7.00	18.00	11.4000	3.01262
CII	30	5.00	16.00	9.0667	2.19613

Table III: Results of Independent samples T- Test

Independent Samples Test					
	t	df	Sig. (2-tailed)	Mean Difference	Std. Error Difference
UPAS	3.428	58	0.001	2.33333	0.68066

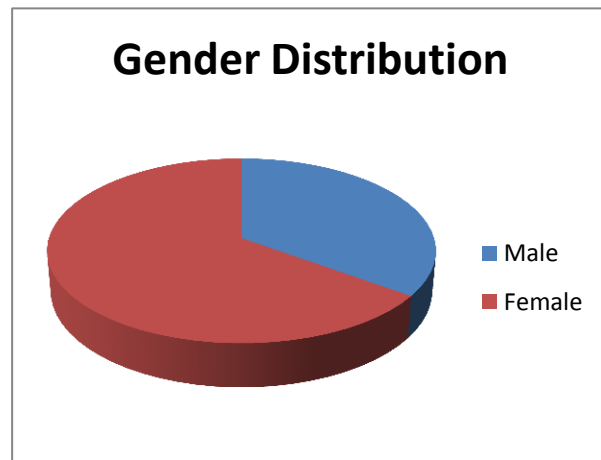


Figure 1: Overall percentage of male and female gender.

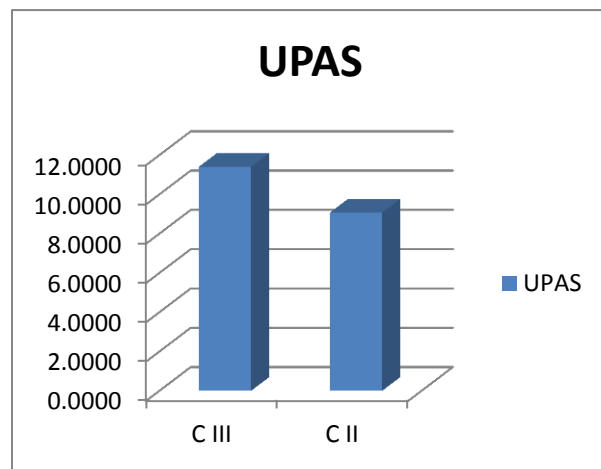


Figure 2: Means for upper pharyngeal airway space

The sample was divided into two groups; group 1 consisted of thirty subjects with Class II malocclusions and group II consisted of thirty subjects with Class III malocclusion. The skeletal pattern was Classified from the lateral cephalograms using ANB angle, with angle greater than 4° taken as Class II and less than 0 taken as Class III skeletal patterns.

The upper pharyngeal airways were measured according to the method of *McNamara Air-way Analysis*. Upper airway width was measured from point on posterior outline of soft palate to closest point on posterior pharyngeal wall, taken on anterior half of soft palate. For inter examiner reliability, measurements for 15 randomly selected patients were repeated by an equally trained examiner, 15 days after the original measurements. For intra examiner reliability, the same examiner repeated the measurements for 15 randomly selected patients almost one month after the first measurements.

The data were analyzed in SPSS version 10. Means and standard deviations for the upper and lower airway space were calculated. Independent t-test was used to compare upper airway space in Class II and Class III malocclusions.

Results

The mean and standard deviation for the measurements of the UPAS in the two skeletal patterns were smaller in the skeletal Class II group and higher in the skeletal Class III group (Figure 2). Results of independent t-test showed statistically significant p-value smaller upper and lower airway dimensions in Class II patients. (Table II & III)

Discussion

Roentgenography and eventually Cephalometrics has provided the orthodontists with an ability to see beneath soft tissue, which gave them greater insight into most of the hard and soft anatomical structures that contribute to facial growth and development. Ricketts¹⁴ pointed out the value of an x-ray cephalometric examination in his publications dealing with nasopharyngeal anatomy and its relationship to tongue posture in children. He noted that certain children who presented for orthodontic treatment with open bites, constricted palates

and high mandibular plane angles also had medical histories that included allergies, adenoid and tonsillar enlargement and mouth breathing patterns. In this study, skeletal Class II and III patients with no pharyngeal pathologies, allergies or adenoids were included to omit the confounding effects of vertical discrepancies and above mentioned factors.

In this study, patients of two different sagittal patterns were included and it was found that smaller airway dimensions prevailed in Class II skeletal pattern and wider airway dimensions in Class III patients.

Paul and Nanda⁷ found greater prevalence of mouth breathing and nasopharyngeal airway obstruction in subjects with Class II malocclusions.

Moto et al⁹ studied the antero-posterior diameter of the pharyngeal airway space (PAS) at the level of the soft palate and base of the tongue in lateral cephalograms of age-matched females with a normal mandible (n=31), mandibular retrognathism (n=30) or mandibular prognathism (n=38). The results showed clear-cut differences in the PAS among the three groups. Pharyngeal airway diameter was largest in the group with mandibular prognathism followed by the normal mandible and mandibular retrognathism groups. These results indicated that the antero-posterior dimension of the PAS is affected by different skeletal patterns of the mandible. This study also shows significantly smaller airway in Class II patients with retrognathic mandible and larger airway in Class III patients with prognathic mandible (Fig 2).

The anteroposterior position of the mandible most likely affects the position of the base of the tongue because the tongue is connected to the inner surface of the anterior mandible by the genioglossus muscle. Comminuted fractures of the anterior mandible are associated with glossoptosis, leading to pathologic sequelae. This condition is caused by the fracture induced posterior shift of the

attached area of the genioglossus muscle. Pierre Robin syndrome is also often associated with glossoptosis (a retrognathic mandible holding the tongue back), thus restricting the PAS. Oral appliances are a viable option for treating patients with OSA syndrome, especially because a retrognathic mandible is often involved.^{15, 16} Treatment with oral appliances is designed to reposition the mandible and tongue anteriorly, thereby enlarging the airway. From the present results, demonstrating a direct relationship between the position of the mandible (mandibular retrognathism, normal subjects and mandibular prognathism) and the PAS, the use of oral appliances may be acceptable. Interestingly, the results show that the PAS-UP (PAS at the level of soft palate) differed among the two groups (Table II), whereas the position of the maxilla did not. The PAS was larger in Class III group, than Class II group. From these results, it is suggested that the PAS-UP was not affected by maxillary size and position.

Although lateral cephalometric radiographs provide 2-dimensional images of the nasopharynx^{17, 20} which consists of complex 3-dimensional anatomical structures. Linder-Aronson¹⁹ found a high level of correlation between the results of posterior rhinoscopy and radiographic cephalometrics in the assessment of adenoid size and nasopharyngeal airway.

The results indicate that the UPAS is more narrow and collapsible in Class II group. Many patients with retrognathism show contact between the soft palate and tongue because of downward displacement of the tongue. In supine position the tongue is situated ventrally to the soft palate and can push the soft palate dorsally, changing the PAS. During sleep, airway narrowing may occur as a result of posterior displacement of the soft palate.^{18, 21} Class II skeletal pattern may be the most important risk factor for upper airway obstruction.

Conclusions

- A positive correlation was found between skeletal malocclusion and airway dimensions.
- In patients with Class II skeletal malocclusion upper airway was narrow.
- Patients with Class II skeletal malocclusion either due to short mandibular body or mandibular ramus are more at risk of respiratory problems.

References

1. Baccetti T, Reyes BC, McNamara JA jr. Craniofacial changes in Class III malocclusion as related to skeletal and dental maturation. *Am J Orthod Dentofacial Orthop.* 2007;132:171.
2. Lee DY, Kim ES, Lim YK, Ahn SJ. Skeletal changes of maxillary protraction without rapid maxillary expansion. *Angle Orthod.* 2010;80:504-10.
3. Batool I, Shaheed M, Ali SA, Abbas A. Comparison of upper and lower pharyngeal airway space in Class II high and low angle cases. *Pak O Dent J.* 2010;30:81-4.
4. Freitas MR, Alcazar NMPV, Janson G. Upper and lower pharyngeal airways in subjects with Class I and Class II malocclusions and different growth patterns. *Am J Orthod Dentofacial Orthop.* 2006;130:742-45
5. Malkoc S, Usumez S, Nur M, Donaghy EC. Reproducibility of airway dimensions and tongue and hyoid positions on lateral cephalograms. *Am J Orthod Dentofacial Orthop.* 2005;128:513-16.
6. Sommer T, Ciesielski R, Erbersdobler J, Orthuber W, Fischer-Brandies H. Precision of cephalometric analysis via fully and semiautomatic evaluation of digital lateral cephalographs. *Dentomaxillofac Radiol.* 2009;38:401-6.
7. Chen F, Terada K, Hua Y, Saito I. Effects of bimaxillary surgery and mandibular setback surgery on pharyngeal airway measurements in patients with Class III skeletal deformities. *Am J Orthod Dentofacial Orthop.* 2007;131:372-77
8. Kim YJ, Hong JS, Hwang YI, Park YH. Three-dimensional analysis of pharyngeal airway in preadolescent children with different anteroposterior skeletal patterns. *Am J Orthod Dentofacial Orthop.* 2010;137: 306.
9. Muto T, Yamazaki A, Takeda S. ¹. *Int J Oral Maxillofac Surg.* 2008;37:228-31.
10. De Freitas MR, Alcazar NM, Janson G, De Freitas KM, Henriques JF. Upper and lower pharyngeal airways in subjects with Class I and Class II malocclusions and different growth patterns. *Am J*

- Orthod Dentofacial Orthop. 2006;130:742-745.
11. Arya D, Tripathi A, Singh SV, Tripathi S, Nagar A, Mishara A. A pilot study to evaluate post treatment cephalometric changes in subjects with OSA. *J Prosthet Dent.* 2010;103:170-7.
 12. Gupta RK, Chandra A, Verm, AK, Kumar S. Obstructive sleep apnoea: a clinical review. *J Assoc Physicians India.* 2010 Jul;58:438-41.
 13. Svanholt P, Petri N, Wildschjødtz G, Sonnesen L, et al. Association between craniofacial morphology, head posture, and cervical vertebral body fusion in men with sleep apnea. *Am J Orthod Dentofacial Orthop.* 2009;135: 702-9.
 14. Chen F, Terada K, Hua Y, Saito I. Effects of bimaxillary surgery and mandibular setback surgery on pharyngeal airway measurements in patients with Class III skeletal deformities *Am J Orthod Dentofacial Orthop* 2007;131:372-77.
 15. Imes NK, Orr WC, Smith RO, Rogers RM. Retrognathia and sleep apnea. A lifethreatening condition masquerading as narcolepsy. *J Am Med Assoc* 1977; 237: 1596-97.
 16. Conway WA, Bower GC, Barnes ME. Hypersomnolence and intermittent upperairway obstruction. Occurrence caused by micrognathia. *J AmMed Assoc* 1977; 237: 2740-2742.
 17. Lowe AA, Fleetham JA, Adachi S, Ryan CF. Cephalometric and computed tomographic predictors of obstructive sleep apnea severity. *Am J Orthod Dentofacial Orthop* 1995;107: 589-95.
 18. Trudo FJ, Geffer WB, Welch KC, Gupta KB, Maislin G, Schwab RJ. State-related changes in upper airway caliber and surrounding soft-tissue structures in normal subjects. *Am J Respir Crit Care Med* 1998: 158: 1259-70.
 19. Linder-Aronson S, Backstrom A. A comparison between mouth and nose breathers with respect to occlusion and facial dimensions. *Odontol Revy* 1960;11:343-76.
 20. Proffit WR, Turvey TA, Phillips C. Orthognathic surgery: a hierarchy of stability. *Int J Adult Orthod Orthognath Surg* 1996;11:191-204.
 21. Isono S, Remmers JE, Tanaka A, Sho Y, Sato J, Nishino T. Anatomy of pharynx in patients with obstructive sleep apnea and in normal subjects. *J Appl Physiol* 1997; 82: 1319-26.