

Orthodontic management of anterior crossbite in early permanent dentition: a case report

Nabin Kumar Chaudhary

Abstract

Anterior crossbite affects the smile and frontal aesthetic of the patient. This case report presents an orthodontic management of an adolescent girl of skeletal class I malocclusion and Angle's class III (Right) subdivision with an anterior single tooth in crossbite. Treatment was completed in 28 months with a fixed orthodontic appliance with the extraction of four first premolars and disocclusion of anterior teeth through glass ionomer cement bite block to prevent occlusal interferences. At the end of treatment anterior crossbite was corrected with the achievement of class I molar and canine relation. The smile of the patient improved from a non-consonant smile arc to a consonant smile arc. The proper history, clinical examination, and investigations are of utmost importance to reach a clinical diagnosis and formulation of the treatment plan.

Keywords: Anterior crossbite; fixed orthodontics; glass ionomer cement bite block; smile

Introduction

Anterior teeth play an important role in the smile and frontal aesthetic of the person.¹ Anterior crossbite can spoil the frontal aesthetics and confidence of the patient.¹ Anterior crossbite results from the lingual positioning of maxillary anterior teeth in relation to the mandibular anterior teeth.² Prevalence of anterior crossbite is 6.3% among the Nepalese population.³ The etiological factors include the palatal eruption of maxillary incisors, trauma to the primary incisors, supernumerary anterior teeth, over-retained primary teeth, odontomas, crowding in the incisor region, inadequate arch length, detrimental habit patterns, and repaired cleft lip.⁴ Treatment approaches include tongue blade therapy, lower inclined plane, stainless steel or composite crowns, Hawley retainer with auxiliary springs, and fixed appliances.⁵ Patient compliance affects the success of removable appliance whereas fixed appliance do not require a high level of compliance.⁶ Correction of anterior crossbite is indicated as

soon as diagnosed to prevent the hindrance of normal growth of jaws and disturbances of neuromuscular or temporomandibular joint function. Also eliminates traumatic occlusion to the incisors which could lead to dehiscence and gingival recession.⁷

Diagnosis

A 14-year female patient presented with the chief complaint of irregular teeth in the left upper front region of the jaw. On clinical examination, the build was mesomorphic, head brachycephalic (cephalic index 94.1%), face mesoprosopic (facial index 88%), and facial form was square tapering. The profile of the patient was straight, facial divergence was anterior, acute nasolabial angle, competent lips, normal mentolabial sulcus, and both lip length and commissure height were 21 mm (Figure 1). On functional examination, the patient had difficulty speaking letters like /d/ and /z/. Oral hygiene status was normal and brushing habit was regular with fluoridated toothpaste. No abnormalities were detected in soft tissues. On hard tissue examination, the number of teeth present clinically was 27 and unerupted teeth were 17, 18, 28, 38, and 48. Maxillary arch was

Dental Department, Consultant Orthodontist,
Hetauda Hospital, Hetauda, Nepal.
Email: cnabin39@gmail.com

ovoid, asymmetrical, and with anterior crowding. Mandibular arch was ovoid, asymmetrical, and with anterior crowding. The maximum mouth opening was 54 mm, with a freeway space of 3 mm and a curve of spee of 1.5 mm. Molar relation was super class I on right side and class I on left side. Incisor relation was class I with overjet of 1 mm, and overbite of 1.5 mm/18.8% (Figure 2). Thus dental diagnosis was Angle class III (Right) subdivision. This was also confirmed through the study model (Figure 3). Upper dental midline was shifted to left by 1 mm and lower dental midline was coincident with the facial midline. On smile analysis, lip line was suggestive of the average lip line, non-consonant smile-arc, straight upper lip curvature, complex smile style, presence of buccal corridor, and shape of upper central

incisor was square with golden standard of 100% (Figure 1). The total score for ABO discrepancy index was 7 (1 for overjet, 4 for amount of crowding in mandible, and 2 for occlusion). On orthopantomogram (OPG), no tooth bud was found for 18 and 28. No other abnormalities were detected on OPG (Figure 4). An intraoral periapical radiograph (IOPAR) with respect to (w.r.t.) upper incisors didn't show any pathologies associated with it (Figure 5). Lateral cephalogram showed cervical vertebrae maturation stage at stage 4. Cephalometric tracing revealed skeletal class I pattern with ANB 0° with normal growth pattern (FMA= 25°). Upper and lower lips were placed ahead of Steiner's S line suggestive of protrusive upper and lower lips (Figure 6).

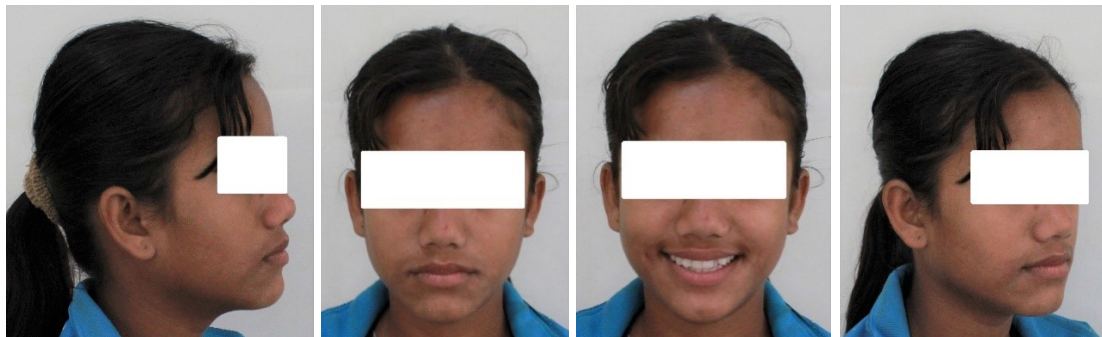

Figure 1: Pretreatment extra-oral photographs

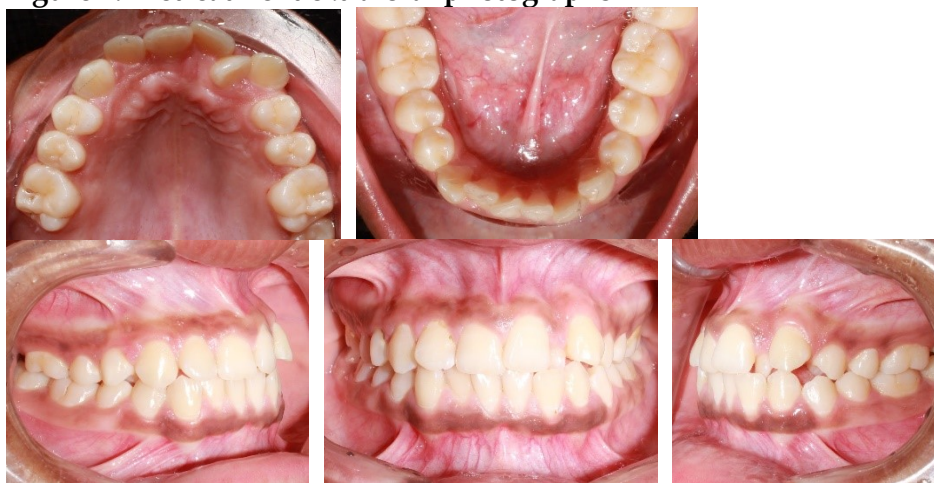

Figure 2: Pretreatment intraoral photographs

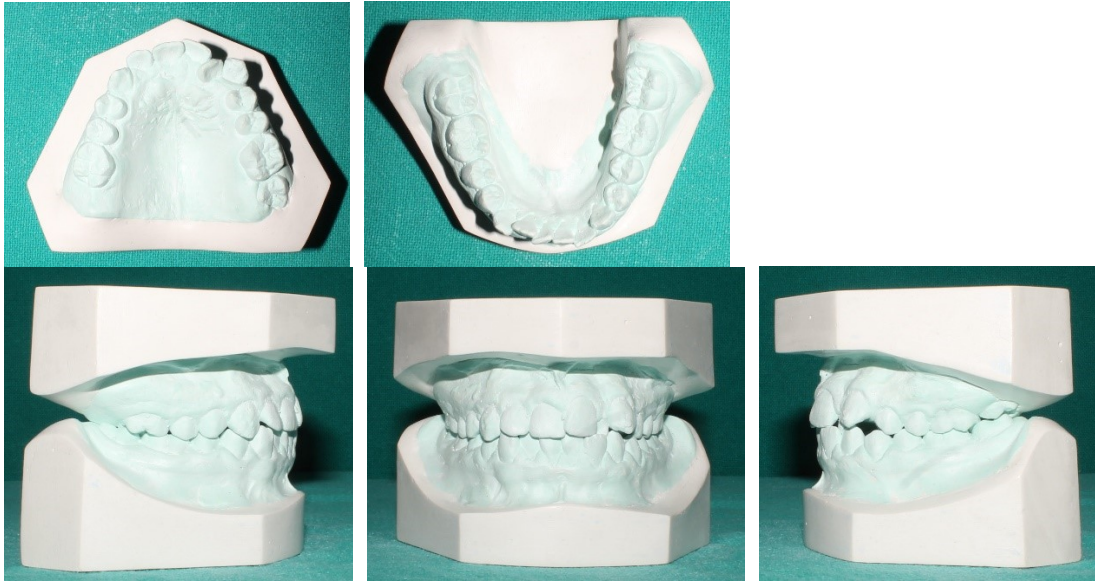


Figure 3: Pretreatment study model

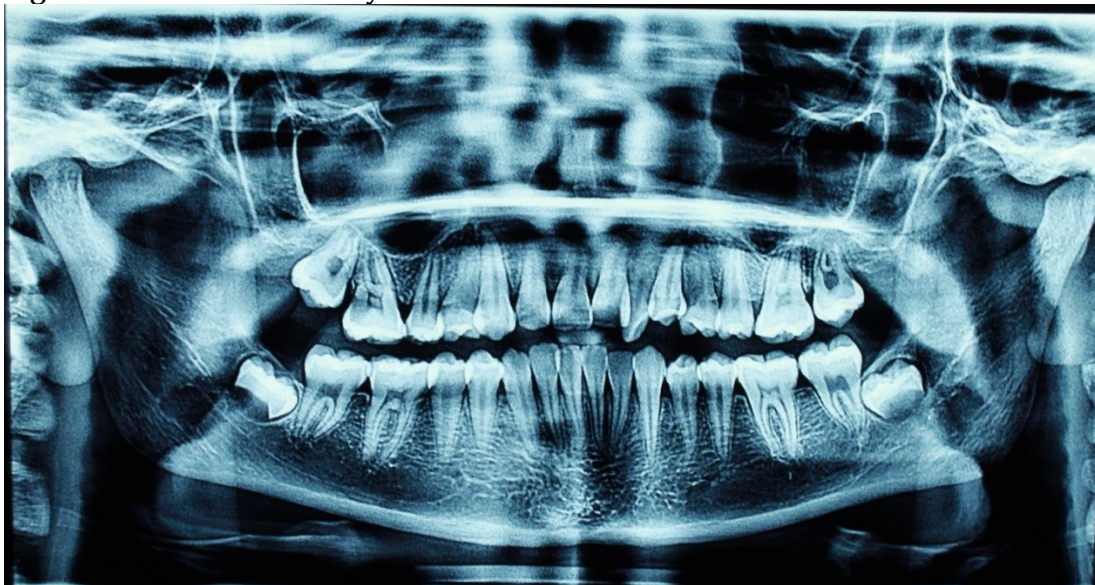

Figure 4: Pretreatment OPG

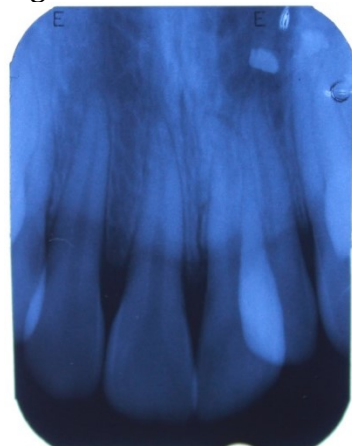


Figure 5: IOPAR w.r.t. upper incisors

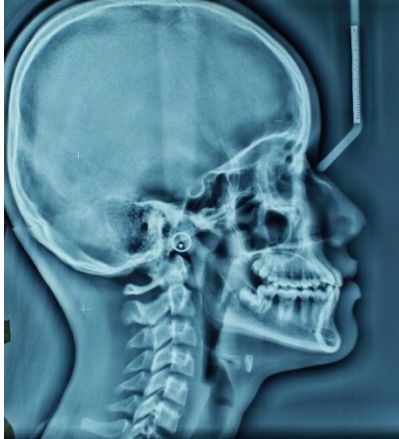

Figure 6: Pretreatment lateral cephalogram

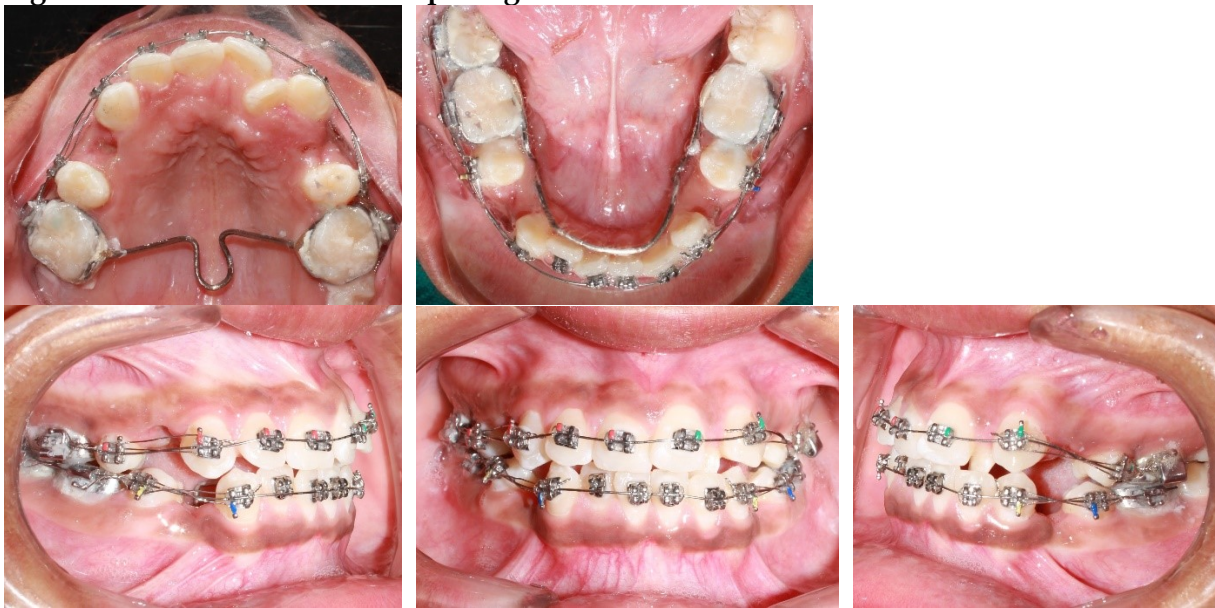

Figure 7: Bonding of upper and lower arch

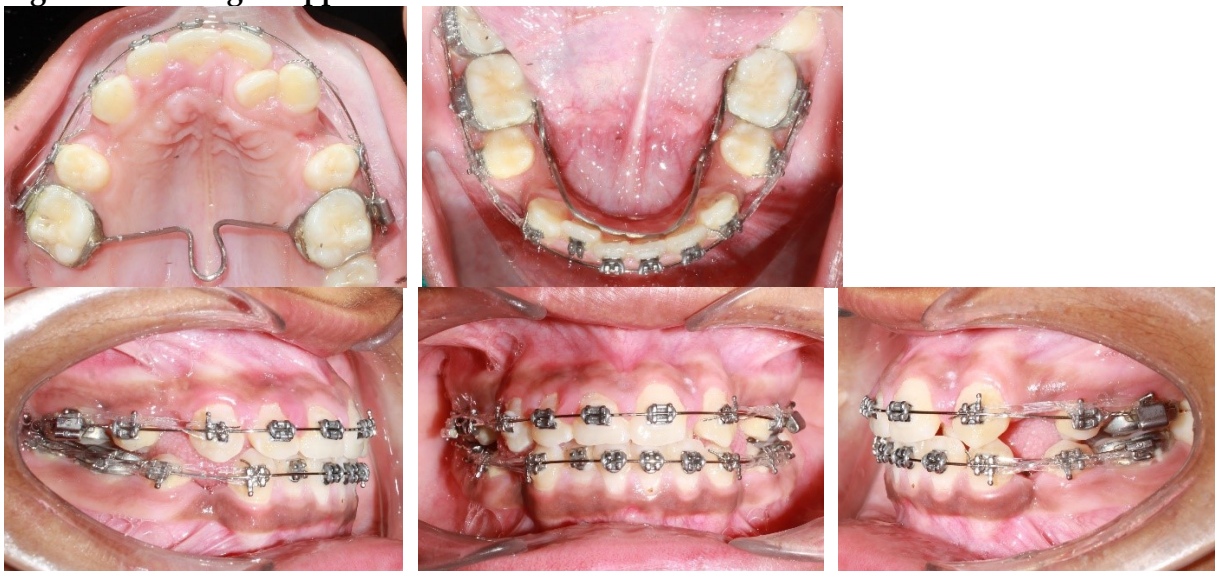


Figure 8: Canine retraction started

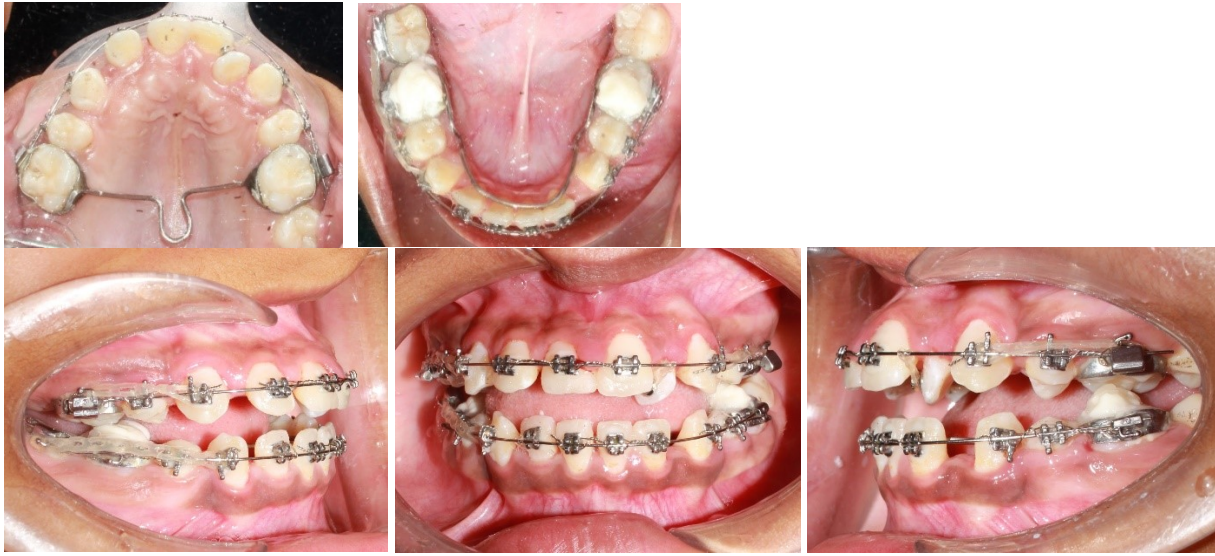


Figure 9: GIC bite block placed to raise anterior bite, correction of crossbite w.r.t. 22 started

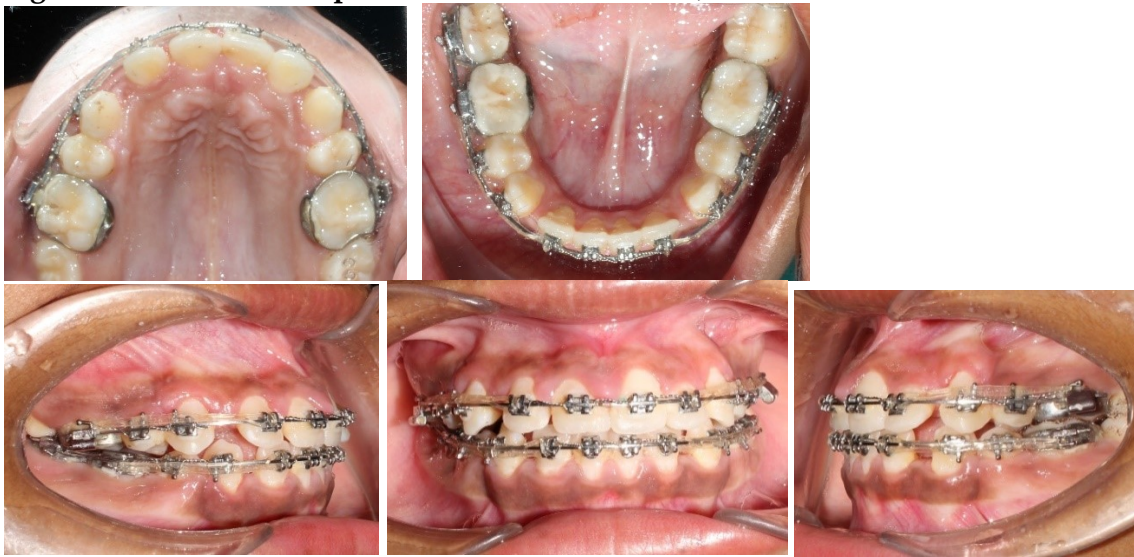


Figure 10: Anterior retraction started

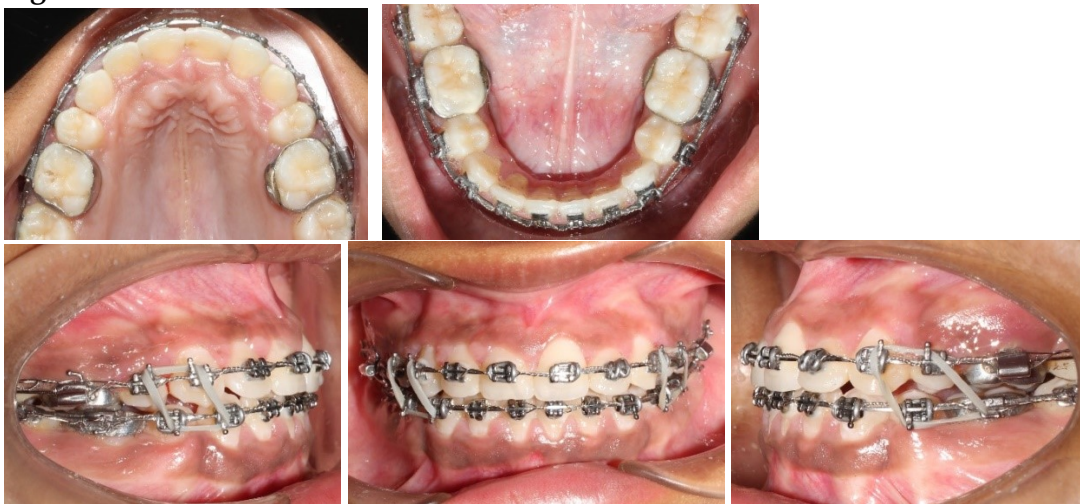

Figure 11: Posterior elastics for settling

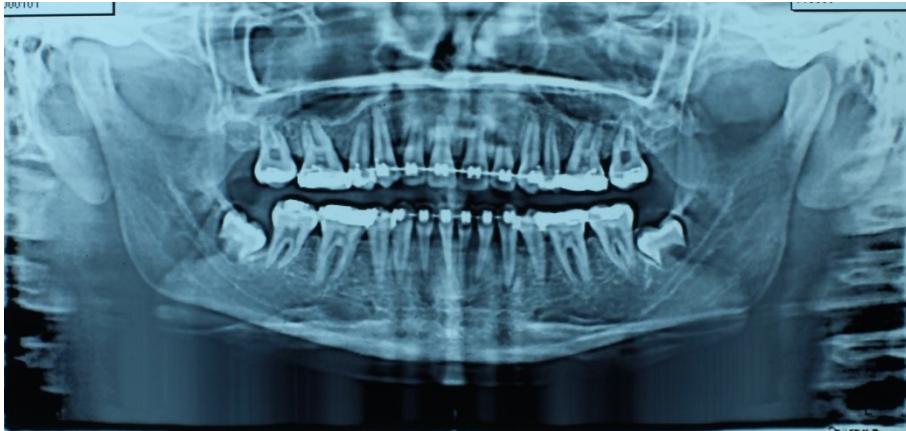


Figure 12: OPG before debond

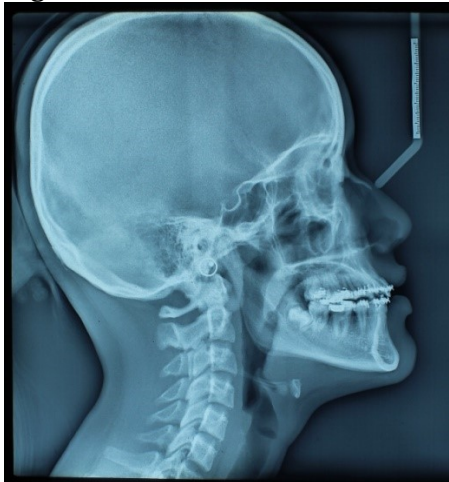


Figure 13: Lateral cephalogram before debond

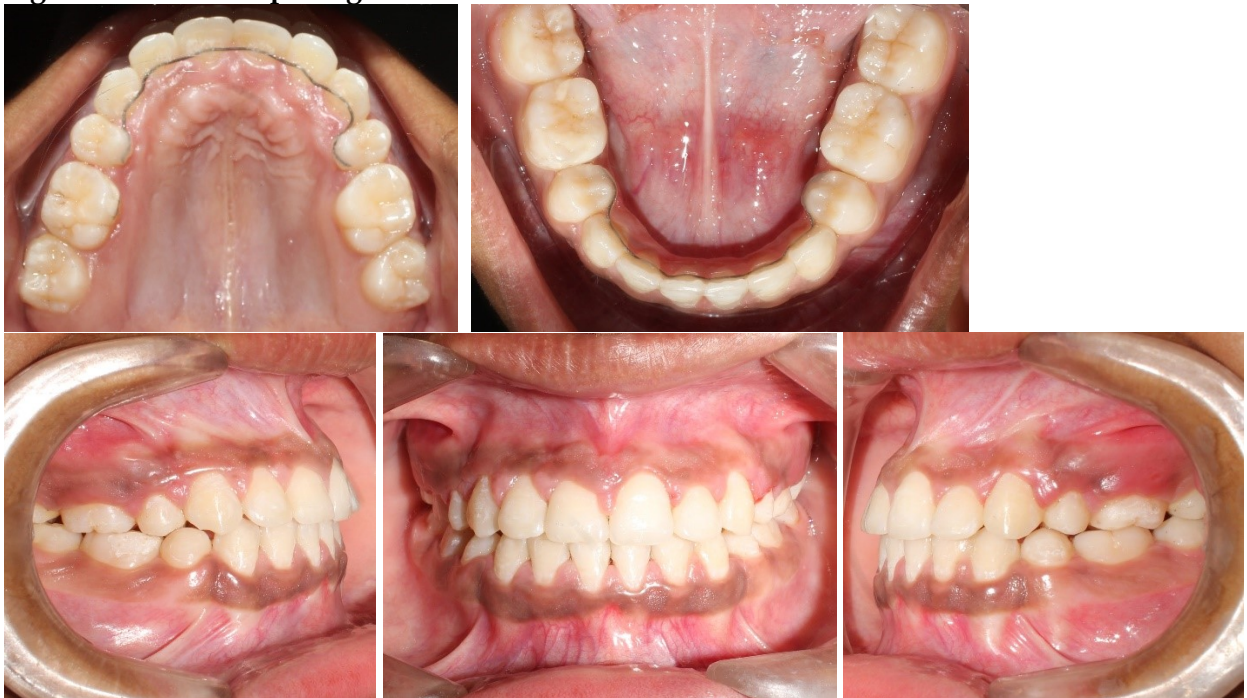

Figure 14: Intra-oral photographs post debond

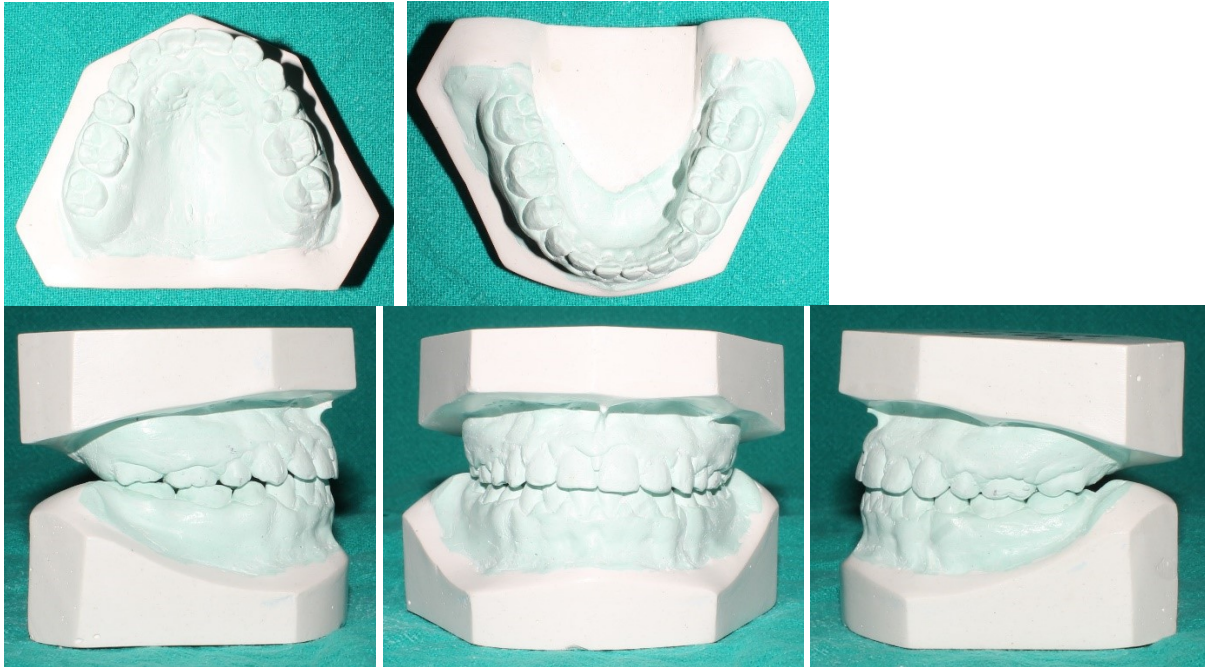

Figure 15: Post-treatment study model

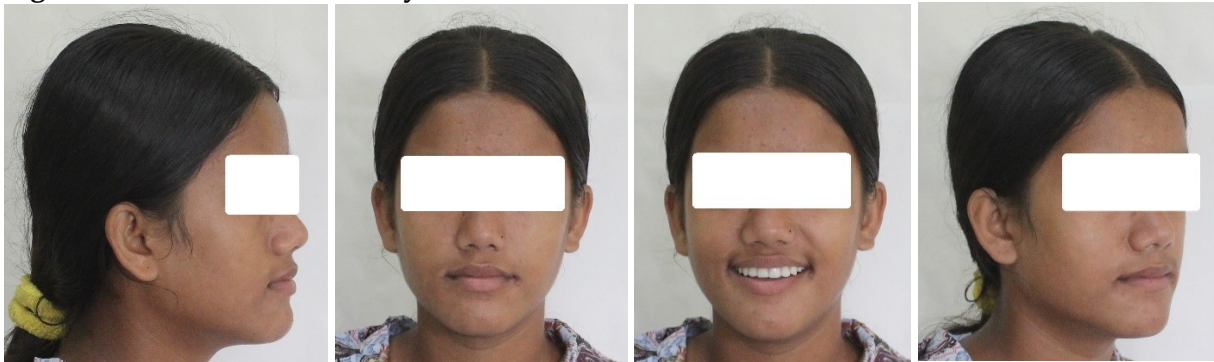

Figure 16: Extra-oral photographs post debond

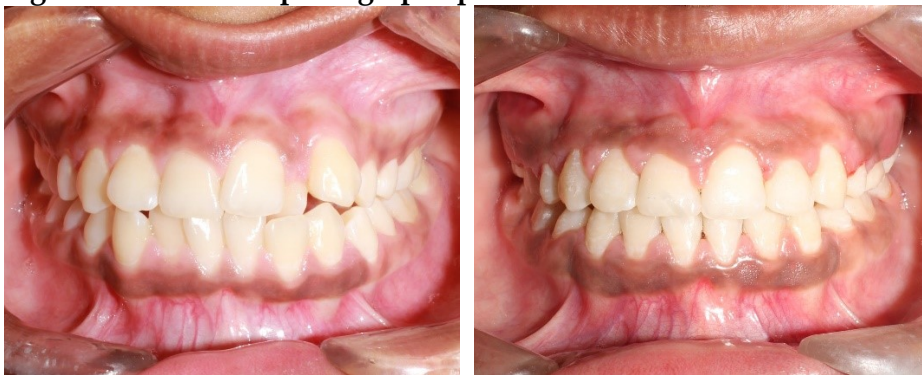

Figure 17: Comparison of intra-oral frontal photographs before and after treatment

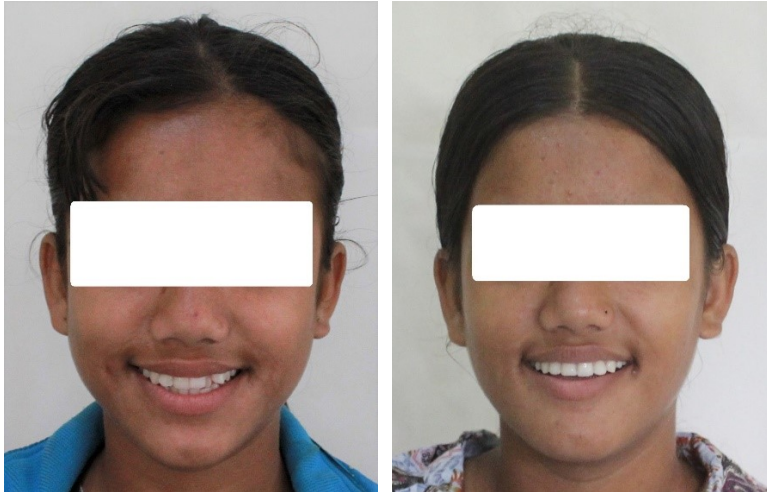

Figure 18: Comparison of extra-oral frontal photographs before and after treatment on smiling

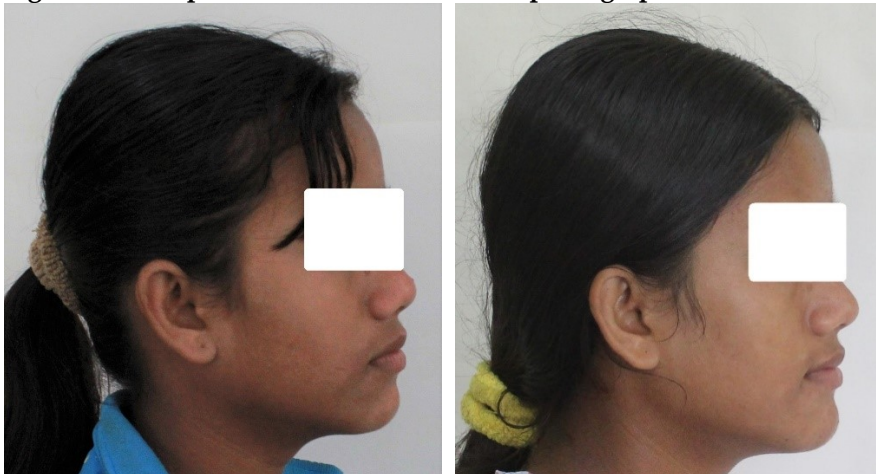

Figure 19: Comparison of profile photographs before and after treatment




Figure 20: Cranial base superimposition

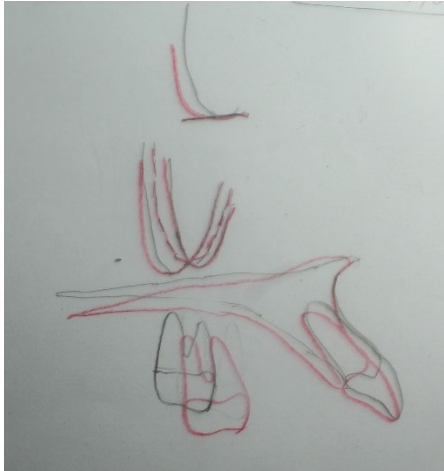


Figure 21: Maxillary superimposition

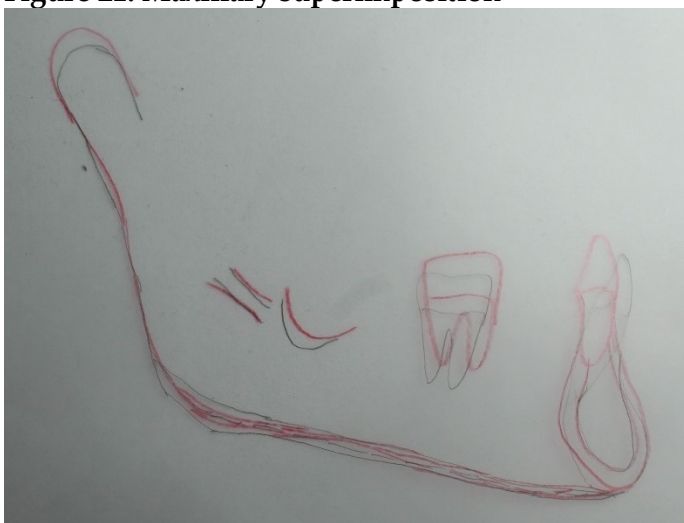


Figure 22: Mandibular superimposition

Table I: Cephalometric values pre and post treatment

Parameters	Normal value	Initial value	Post treatment	Difference
SNA	82°±2°	82°	82°	0°
SNB	80° ±2°	82°	82°	0°
ANB	2° ±2°	0°	0°	0°
FMA	25°	25°	24°	1°
U1-NA (°/mm)	22° /4 mm	29° /7 mm	26° /4 mm	-3° /-3 mm
L1-NB (°/mm)	25° /4 mm	32° /5 mm	18° /2 mm	-14° /-3 mm
S-line to upper lip	0 mm	0.5 mm	-0.5 mm	-1 mm
S-line to lower lip	0 mm	2 mm	0 mm	-2 mm

Etiology

The etiology of this malocclusion was the lack of space for the tooth in crossbite. The skeletal relationship between maxilla and mandible

was normal. This malocclusion was dentoalveolar as a single tooth was in crossbite.

Treatment objectives

Treatment objectives include correction of crossbite w.r.t. 22, bimaxillary dentoalveolar protrusion, decreased overjet and overbite, upper dental midline shift, lip protrusion, speech problem, and obtain class I molar and canine relation on both sides.

Treatment alternatives

Treatment options were

- a) Fixed appliance therapy with non-extraction approach
- b) Fixed appliance therapy with extraction of four premolars

Second option was opted as there was lack of space for alignment of 22 in crossbite. As incisors were already proclined and lips protrusive, the creation of space for 22 would further procline incisors and make lips protrusive. Thus, the non-extraction treatment approach was avoided as it would worsen the patient's facial profile.

Treatment progress

After the extraction of 14, 24, 34, and 44 bonding of 0.022" x 0.028" slot MBT bracket was done both in upper and lower arches (Figure 7). Maximum anchorage was planned on mandible right side, moderate anchorage on mandible left side, and moderate anchorage on both sides of maxilla. Transpalatal arch and lingual holding arch were placed in maxilla and mandible respectively as a means of anchorage during alignment and leveling and also during canine retraction phase. Second molar banding was done on mandibular right side to reinforce anchorage. 0.014" Nickel-Titanium (NiTi) then 0.016" NiTi was placed in maxilla before partial retraction of canine. Laceback and bendback were given to prevent proclination of incisors during alignment and leveling phase. Initial retraction of 23 was done until enough space was available for 22 (Figure 8). Glass ionomer cement bite block was used for disocclusion of anterior teeth (Figure 9). Two-stage retraction was planned. Canine retraction was done in 0.018" SS. Anterior retraction was

done in 0.019"x0.025" SS (Figure 10). For the correction of torque w.r.t. 22 the bracket was placed in an inverted position for 2 months. Settling elastic 3/16" 4.5-ounce force was used for settling occlusion (Figure 11). OPG showed paralleling of roots with each other (Figure 12). Lateral cephalogram showed correct inclination of incisors (Figure 13). Thus debonding and debanding were done. Lingual bonded retainer was used as a retainer in both upper and lower arch from premolar to premolar as it was an extraction case so that space doesn't open in premolar and canine region. In the end, there was class I molar and class I canine relation on both sides (Figure 14). The study model was also prepared at the end of treatment with fixed retainer in place (Figure 15). The total treatment duration was 28 months.

Results and discussion

The final results showed attainment of all functional and esthetic goals. The radiographic evaluation confirmed the correction of the inclination of upper and lower incisors. An ideal amount of overjet and overbite were established and crossbite corrected. The extraction treatment approach was chosen for this patient as space was not available for 22 to bring into the arch and the creation of space would result in more proclined incisors and protrusive lips. GIC bite block was used to disocclude anterior teeth for avoiding occlusal interferences for the correction of crossbite w.r.t 22. Retraction of incisors to correct bimaxillary dentoalveolar protrusion has been achieved. The ideal amount of overjet and overbite has been achieved. The upper dental midline shift was corrected, that is, upper dental midline coincides with lower dental midline which in turn is coincident with facial midline. The lip protrusion was reduced with retraction of incisors. The speech problem was corrected with the correction of crossbite. The class I molar and canine relation on both sides has been achieved (Figures 16, 17, 18, and 19). The smile of the patient improved from a non-

consonant smile arc to a consonant smile arc. There were no changes in the skeletal bases of maxilla and mandible and their relationship with each other. The proclined incisors and protrusive lips changed towards the ideal values after treatment (Table I). The superimposition of pretreatment and post-treatment lateral cephalogram showed no growth changes in maxilla, downward growth of mandible, a slight decrease in prominence of upper and lips, lower incisors retraction, maintenance of lower molar position, maintenance of upper incisors position, and protraction of upper molar (Figures 20, 21 and 22).

The study,⁸ found anterior crossbite can be successfully corrected by either fixed or removable appliances with similar long-term stability. However, this case report was treated with fixed appliance as comprehensive treatment was planned for the patient in early permanent dentition but not in mixed dentition. The study by Vasilakos et al,⁵ placed resin-modified GIC to raise the bite 1-2 mm anteriorly which resulted in spontaneous correction of anterior crossbite in 2.5 months. This study was different from the present case report as it was treated in early permanent dentition whereas Vasilakos et al,⁵ performed the study in mixed dentition. Ritter,¹ performed the correction of anterior crossbite with the use of a similar fixed appliance. However, Ritter,¹ performed treatment through the non-extraction mode of treatment whereas the present case report was treated with the extraction mode of treatment. Study,² treated anterior crossbite through the use of Catalan's appliance for 3 weeks. Catalan's appliance was successful in treatment of anterior crossbite as space was available for the tooth in crossbite.² This treatment approach was not possible in the present case report as there was lack of space for the tooth in crossbite. Another study,⁴ used an upper removable acrylic appliance with an expansion jackscrew to correct the crossbite. The removable appliance was successful in treatment as adequate space was

available for the tooth in crossbite which was not the same in the case of this presented case report.⁴ Recently clear aligners can also be used for the correction of anterior crossbite.⁹ However, this treatment approach was not used in this patient because of the cost factor and complex tooth movements are not possible with clear aligner.⁹ The study Arm-Rey et al showed an association between dental malocclusions and phonetic alterations.¹⁰ In the presented case report, the patient had difficulty in pronouncing /d/ and /z/ which was corrected with the correction of anterior crossbite.

The patient was satisfied as the treatment objectives were achieved at the end of treatment. One of the demerits of this case report was the long treatment duration. However, this was unavoidable as proper follow-up was not possible due to the COVID-19 lockdown. The proper history, clinical examinations, and investigations are of utmost importance for clinical diagnosis, formulation of the treatment plan, and use of the right appliance for the treatment.

Consent

Informed consent was obtained for publication in journal as a case report.

Conflict of interest

None

References

1. Ritter DE. Class I malocclusion with anterior crossbite and severe crowding. *Dental Press J Orthod.* 2014; 19: 115-25.
2. Prakash P, Durgesh BH. Anterior Crossbite Correction in Early Mixed Dentition Period Using Catalan's Appliance: A Case Report. *ISRN dentistry.* 2011; 2011: 298931.
3. Baral P. Prevalence of Malocclusion in Western Nepal. *Orthodontic Journal of Nepal.* 2016; 5: 6.
4. Bindayel NA. Simple removable appliances to correct anterior and posterior crossbite in mixed dentition: Case report. *Saudi Dent J.* 2012; 24: 105-13.
5. Vasilakos G, Koniaris A, Wolf M, Halazonetis D, Gkantidis N. Early anterior crossbite correction through posterior bite opening: a 3D superimposition prospective cohort study. *Eur J Orthod.* 2018; 40: 364-71.
6. Tsomos G, Ludwig B, Grossen J, Pazera P, Gkantidis N. Objective assessment of patient

- compliance with removable orthodontic appliances: a cross-sectional cohort study. *Angle Orthod.* 2014; 84: 56-61.
7. Nagahara K, Suzuki T, Nakamura S. Longitudinal changes in the skeletal pattern of deciduous anterior crossbite. *Angle Orthod.* 1997; 67: 439-46.
 8. Wiedel AP, Bondemark L. Stability of anterior crossbite correction: a randomized controlled trial with a 2-year follow-up. *Angle Orthod.* 2015; 85: 189-95.
 9. Abraham KK, James AR, Thenumkal E, Emmatty T. Correction of anterior crossbite using modified transparent aligners: An esthetic approach. *Contemp Clin Dent.* 2016; 7: 394-97.
 10. Leavy KM, Cisneros GJ, LeBlanc EM. Malocclusion and its relationship to speech sound production: Redefining the effect of malocclusal traits on sound production. *Am J Orthod Dentofacial Orthop.* 2016; 150: 116-23.