

Radiographic assessment of the prevalence of maxillary canine impaction according to sector method- A cross sectional study

Madiha Ishfaq^a, Huma Sikandar^b, Zafar Ul Islam^c, Kawish Syed^d, Sadia Nisar Ahmed^e, Shahab Adil^f

Abstract

Introduction: An impacted tooth is the one that fails to erupt at its specific site in the dental arch, within its normal period of development. Determining whether impaction will occur and timing the treatment modalities that are affected by impacted canine (s) are paramount for a successful outcome. The objective of the study was to find out prevalence of sector-wise impacted maxillary canine on panoramic radiographs of patients reporting for orthodontic treatment in a tertiary care hospital.

Material and Methods: This cross-sectional analytical study was conducted on fifty panoramic radiographs of orthodontic patients with canine impaction at a tertiary care hospital using a non-probability sampling technique. The panoramic radiographs were assessed by trained clinical practitioners and maxillary canine impaction was scored using Lindauer et al modified (1992) sector's method. The data was statistically analyzed through SPSS version 20.0. Standard deviations and means of continuous variables were calculated as descriptive statistics. The chi-square test was applied to determine any differences in the distribution of maxillary canine impaction when stratified by location (sector) and gender. The probability value (P value = 0.05) was considered a statistically significant level.

Results: The maxillary canines were more frequently impacted in sector 1 (male: 7, female: 8) and sector 2 (male: 8, female: 10). Unilateral impaction, as compared to bilateral impaction, was found greater in both genders with 32 among 50 cases. No statistically significant difference was found between female and male patients regarding sectors classification and unilateral; or bilateral impaction.

Conclusions: Unilateral maxillary canine impaction was more common than bilateral. The peak of cusp tip of the maxillary canine was more sited in sector 1 and 2 while there was no statistically significant gender difference regarding unilateral versus bilateral and mesio-distal canine position.

Keywords: Orthopantomography; radiography; tooth; unilateral

Introduction

When a tooth does not erupt at its specific location in the oral cavity, in its pre-determined time of development, it is known as an impacted tooth. Maxillary cuspids, after the 3rd molars, are the most commonly impacted teeth with incidence range of 0.9-

3.0%, based on the population inspected.¹ During the phases of transformation, eruption disturbance is usually encountered from primary to mixed and then to permanent dentition. Canine impaction mostly occurs because of eruption disturbances due to its location and emergence pattern. Maxillary canine impaction incidence is up to 5%.² It is

^a BDS. Resident, Department of Orthodontics, Peshawar Dental Hospital, Riphah International University Islamabad.

^b BDS. Lecturer, Department of Orthodontics, Peshawar Dental Hospital, Riphah International University Islamabad.

^c BDS, FCPS. Assistant Professor, Department of Orthodontics, Peshawar Dental College, Riphah International University Islamabad.

^d BDS, MCPS. Assistant Professor, Department of Periodontology, Sardar Begum Dental College, Gandhara University Peshawar, Pakistan.

^e BDS, FCPS. Assistant Professor, Head of department of Orthodontics, Bachakhan College of Dentistry, Khyber Medical University, Peshawar, Pakistan.

^f Corresponding Author; BDS, FCPS. Professor, Department of Orthodontics, Peshawar Dental Hospital, Riphah International University Islamabad, Pakistan.
Email: shahabail@hotmail.com

the fact that maxillary canine impaction happens half, in males than females.³ In orthodontics treatment, patients having no impactions, undergo shorter treatment duration than those having impacted canine, but it depends on dislocation and, position of the tooth from the plane of occlusion.⁴ There are probabilities of deleterious changes in lateral incisor roots and ankylosis of the canine, if orthodontic therapy is delayed.

It is a dilemma for many orthodontists because of difficulty in localization, undetermined response to prophylactic measures and prognosis. For successful orthodontic treatment outcome, prediction of canine impaction and proper treatment planning is important.⁵ Poor esthetics, midline deviation & tipping, it also causes other complications such as root resorption, transpositions, cystic lesions and discomfort in adjoining teeth. The root resorption of adjoining teeth is most frequently reported among these problems. The palatal impactions are predominant over buccal impactions with the reported frequency of 85%.⁶ According to Divakar,⁷ and Ting et al,⁸ the ratio of palatal to buccal impaction is 3:1 and 12:1 respectively. Regardless of the cause, impacted maxillary canines occur with adequate frequency to permit substantial research on possible prophylactic treatment procedures.

To manage this dilemma, presently the utmost effective prophylactic measure is the removal of deciduous canine so that the

permanent canine moves to its proper location. Mesio-distal angulation of the root and inclination of the crown are the two likely indicators of the successful treatment outcome. Manne⁹ reported that there is a reduced possibility of canine eruption after the removal of a deciduous tooth when the crown is more mesially located. Power et al¹⁰ considered root position as an indicator of impaction and proposed that possibilities of eruption decreases after deciduous tooth removal when the tooth-midline angle is greater than 31 degrees. Schindel et al¹¹ followed Ericson and Kuroi method, that the possibility of canine impaction relies upon the cusp tip position in one to four sectors and figured out that the seventy-eight percent of the intended impactions have cusp tips present in sector 2, 3, & 4.

The objective of the study was to find out prevalence of sector-wise impacted maxillary canine on panoramic radiographs of patients reporting for orthodontic treatment in a tertiary care hospital in Peshawar.

Material and Methods

After approval from ethical committee, the study was conducted on fifty panoramic radiographs obtained from the patients reporting to tertiary care dental hospitals of Peshawar regardless of their gender. The patients were included who fulfilled the study criteria of having age greater than 12 years, fully erupted maxillary molars and incisors, unerupted canines and premolars, patients with skeletal and dental class I, II, III relationships. Those who had history of trauma, orthodontic treatment and any related surgery, craniofacial syndromes and known history of mental/psychological derangement were excluded. After explaining the aim of the study, informed consent was obtained from each study's participant. All panoramic images were positioned on an illuminator screen & the surrounding region of the images was protected with a black paper to inhibit hindering lateral light & enhance contrast view. The images were

evaluated by two trained practitioners and then maxillary canine impaction was scored on OPG using Lindauer et al modified (1992) sector method Fig 1:

Sector I: if the tip of the canine lies between the long axis of the 1st premolar and the lateral incisor.

Sector II: if the tip of the canine lies between the distal and half of the lateral incisor.

Sector III: if the tip of the canine lies between the mesial and middle of the lateral incisor.

Sector IV: if the peak of the canine lies mesial to lateral incisor.

Descriptive statistics were applied which include the mean value, median and standard deviation. The chi-square test was used to determine any differences in the distribution of maxillary canine impaction when stratification was done for gender and location (sector). The probability value (P value= 0.05) was considered a statistically significant level.

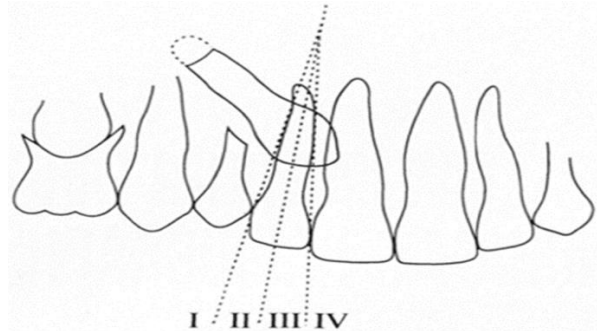


Figure 1: Lindauer et al modified (1992) sector method

Results

Total 50 patients were subjected to clinical and radiographic examination for canine impaction. Among them 29 (58%) were female & 21 (42%) were male (Table I). The age group varies from 13-26 years with the mean age of 17.90 years. The sum of impacted maxillary canine in sector 1, 2, 3 and 4 were found 15 (male: 7, female: 8), 18 (male: 8, female: 10), 11 (male: 4, female: 7) and 6 (male: 2, female: 4) respectively (Table I).

Table I: Prevalence of maxillary canine impaction based on the gender by sector method

Gender	Percentage %	Canine impaction				Pearson Chi-Square		
		Sector I	Sector II	Sector III	Sector IV	Value	Df.	Asymp.Sig. (2-sided)
Male N=21	42	7	8	4	2	.507 ^a	3	.917
Female N=29	58	8	10	7	4			
Total N=50	100	15	18	11	6			

Table II: Prevalence of maxillary canine impaction based on the gender and side of impaction

		Unilateral vs. bilateral		Percentages %	Pearson Chi- Square		
		Unilateral	Bilateral		Value	Df	Asymp. Sig. (2-sided)
Gender	Male	11	10	64	2.122 ^a	1	.145
	Female	21	8	36			
Total		32	18	100			

Unilateral impaction, as compared to bilateral impaction, was found greater in both genders with 32 among 50 cases (21 in females & 11 in males) (Table II). No statistically significant gender difference was found regarding the sector's classification and unilateral; or bilateral impaction (Table I and II).

Discussion

The primary aim of this study was to evaluate the frequency of impacted maxillary canines, as determined by sector analysis (mesio-distal horizontal location of tip of the impacted canine), in the Khyber Pakhtunkhwa population and its correlation with the gender. Canine impaction was analyzed mesio-distally, as demonstrated by sectors from 1-4, wherever sector 1 was the easiest impaction to manage & the sector 4 was the extreme severe & the complicated impaction to manage.¹² The frequency of maxillary canine impaction was relatively high. Alignment of the impacted maxillary canine in a regular dental arch has become a usual task of orthodontic treatment. The highest incidence of impaction was found in sector 1 (30%), and sector II (36%).

Schindel et al¹¹ reported that seventy-eight percent (78%) of impactions fall in sector 2, 3 & 4. This result failed to be in accordance with the current study in which sixty-six (66%) of canines, which would ultimately be impacted were located in sector 1 & 2. Manne⁹ found that if the crown tip is positioned more mesially, the probability of eruption reduces after extraction of primary canines. In routine panoramic investigation of the mixed dentition's patient, maxillary canine impaction was seen when the canine cusp overlays the distal half of the lateral incisor root, or when the peak of the canine cusp lies mesial in relation to the major axis of the lateral incisor root. This study result is in accordance with the present study.

Attempts have to be made initially, as a clinician detects early signs of canine impaction to prevent it. Clinically, the ectopic maxillary permanent canines are commonly

seen, and therefore, in class I cases Williams¹³ recommended the interceptive approach to impacted canines by early removal of the baby canines by the age of eight or nine years. Ericson and Kuroi¹⁴ proposed that extraction of baby canine prior to 11 years of age would help in eruption of permanent cuspid in normal position in dental arch. John H W et al¹⁵ revealed that sector position was a striking indicator of impaction status which is in agreement with the present study. In our study impacted maxillary canines were more frequently found in females (58%) and, this was accordance to other studies such as by Nieri,¹⁶ Jason,¹⁷ Manne.⁹ In the present study, unilateral maxillary canine impaction occurred more commonly (64%) than bilateral impaction (36%). This allocation agreed with those documented by Becker¹⁸ and Ahmad et al¹⁹ who reported 54.6% and 63.2% of unilateral impaction and 45.4% and 38.8% of bilateral impaction respectively.

Conclusions

The stated frequency of maxillary canine impaction was comparable to that found in the previous studies. It is presented, more often in females, with unilateral impaction, more common than bilateral. The half of the canine impactions were in sector 3 and 4, while the mesio-distal position of the cusp tip of the canine was positioned more commonly in sector 1 & 2. In relation to the mesio-distal position of the canine cusp tip, there was no statistically significant gender difference.

References

1. Liu DG, Zhang WL, Zhang ZY, Wu YT, Ma XC. Localization of impacted maxillary canines and observation of adjacent incisor resorption with cone-beam computed tomography. *Oral Surg Oral Med Oral Pathol Oral Radiol Endod.* 2008;105(1):91-8.
2. Khan H, Ashraf A, Anwar A, Najam E, Ahmad F, Khan T. Prevalence and Patterns of Impacted Maxillary Canines: A Cbct based retrospective study. *Pak Oral Dental J.* 2018;38(2):211-214.
3. Becker A, Chaushu S. Etiology of maxillary canine impaction: a review. *Am J Orthod Dentofacial Orthop.* 2015;148(4):557-67.

4. Stewart J, Heo G, Glover K, Williamson P, Lam E, Major P. Factors that relate to treatment duration for patients with palatally impacted maxillary canines. *Am J Orthod Dentofacial Orthop.* 2001;119(3):216-225.
5. Naoumova J, Kurol J, Kjellberg H. Extraction of the deciduous canine as an interceptive treatment in children with palatal displaced canines. *Eur J Orthod.* 2015;37(2):209-18.
6. Al-Zoubi H, Alharbi AA, Ferguson DJ, Zafar MS. Frequency of impacted teeth and categorization of impacted canines: A retrospective radiographic study using orthopantomograms. *Eur J Dent.* 2017;11(1):117-121.
7. Divakar DD. Association between canine impaction and skeletal pattern in the sagittal and vertical planes. *Int J Periodont Rest.* 2020;40(2):253-259.
8. Ting SR, Quick AN, Winters J. The impacted maxillary canine: revisiting the clinical guideline, with case illustrations. *N Z Dent J.* 2011;107(1):19-23.
9. Manne R, Gandikota C, Juvvadi SR, Rama HR, Anche S. Impacted canines: Etiology, diagnosis, and orthodontic management. *J Pharm Bioallied Sci.* 2012;4(2):234-238.
10. Naoumova J, Kjellberg H. The use of panoramic radiographs to decide when interceptive extraction is beneficial in children with palatally displaced canines based on a randomized clinical trial. *Eur J Orthod.* 2018;40(6):565-74.
11. Schindel RH, Duffy SL. Maxillary transverse discrepancies and potentially impacted maxillary canines in mixed-dentition patients. *Angle Orthod.* 2007;77(3):430-5.
12. Algerban A, Jacobs R, Van K, Aly M, Swinnen S, Fieuws S, Willems G. The effect of using CBCT in the diagnosis of canine impaction and its impact on the orthodontic treatment outcome. *J. Orthod. Sci.* 2014;3(2):34 - 37.
13. Abu-Hussein M, Watted N, Hussein E, Proff P, Watted A. Maxillary Impacted Canines; Clinical Review. *Inter J Dent Med Sci Res.* 2017;1(6):10-26.
14. Hsu YC, Kao CT, Chou CC, Tai WK, Yang PY. Diagnosis and Management of Impacted Maxillary Canines. *Taiwan J Orthod.* 2020;31(1):4-11.
15. John H, Ram K, Daniel E. Prediction of maxillary canine impaction using sector and angular measurement. *Am J Orthod Dentofacial Orthop.* 2003;124(6):651-655.
16. Nieri M, Crescini A, Rotundo R, Baccetti T, Cortellini P, Pini Prato GP. Factors affecting the clinical approach to impacted maxillary canines: A Bayesian Network Analysis. *Am J Orthod Dentofacial Orthop* 2010;137(6):755-762.
17. Jason C, Home W. Canine impactions: incidence and management. *Int J Periodontics Restorative Dent.* 2006;26(5):483-491.
18. Rahamneh A, Al-Weshah M, Ghozlan MA, Smadi H, Abu-Odeh R. Prevalence and severity of ectopic maxillary canine impaction in Southern Jordanian population: A radiographic sector analysis. *J R Med Serv* 2017;102(4290):1-7.
19. Ahmed A, Moataz A, Sultana A. Prevalence of maxillary canine impaction in orthodontics at eastern Riyadh specialized dental center. *J Dent Med Sci.* 2017;16(1):72-74.