

Predicting the outcome of bone grafting for dental implants based on the type of bone graft

Ali Khan^a, Imran Khan Yusufzai^b, Madiha Shamsheer^c

Abstract

Introduction: Multi-disciplinary cases often require provision of dental implants. Many a times, orthodontic cases are finished with the provision of space for the surgeons to place prosthetic implants. Such patients may require bone augmentation through bone grafts. Hence a retrospective study was conducted to compare different types of bone grafts i.e. allograft, alloplast and combination of the two and their impact on the success of dental implants.

Material and Methods: It was a retrospective study. Three subsets / arms were established. In Arm A, 32 patients were treated with autografts, in arm B, 49 patients were treated with allografts and in arm C, 26 patients were treated with a combination of allografts and autografts. Cases were considered successful if implants were stable with minimal levels of bone resorption, six months following loading.

Results: There was 1 failure each of implant when autograft was used alone or in combination. Hence, we are reporting 96.8% and 96.1% success rate respectively. We have a success rate of 91.8% when allograft was used alone, with 4 failures in the 49 cases of group B. This establishes autograft as a gold standard for bone augmentation in dental implants. Yet allograft remains a popular choice.

Conclusions: Autograft when used alone or in combination with allograft gives reasonable and predictable success. Our study establishes that autograft either harvested intraorally or extraorally remains the gold standard for bone grafting for dental implants. At the same time we see that allografts remain a popular choice as most patients received allografts.

Keywords: Dental implants; bone graft; autograft; allograft; gold standard for bone grafting; bone remodeling; iliac crest graft; success rate of implants; osteointegration; guided bone regeneration

Introduction

The term Osteointegration is defined as the close contact between bone and implant material in histological observations and in clinical terms, as the ankylosis of implants in bone.^{1,2} Dental implants are a prosthetic device of alloplastic material(s) implanted into the oral tissues beneath the mucosal and/or periosteal layer and/or within the bone to provide retention and support for a fixed or removable prosthesis.

Bone remodelling and resorption of the buccal bone plate are inevitable after tooth loss or extraction.³ There is bone resorption even after implant placement considered to be due to surgical trauma and tissue adaptation to the new foreign body. A minimum of 2 mm of buccal bone is ideal to prevent vertical bone resorption.³ There isn't always enough bone for the support of an implant placement. Hence, bone augmentation can be carried out with predictable success. Guided bone regeneration utilizing a variety of materials to rebuild atrophic or resorbed ridges has been studied in various clinical and animal studies.⁴⁻⁶ This bone may be either an autograft⁷⁻¹⁰ or an allograft of freeze-dried bone that is mineralized or demineralised¹¹⁻¹²

^a BDS, MFDS RCSEd, FFD RCSI, F-ICOI; Assistant Professor Oral and Maxillofacial Surgery, Rawal Institute of Health Sciences, Islamabad.

^b Corresponding Author: BDS, MSc, Assistant Professor, Oral Pathology, Islamabad Medical and Dental College, Islamabad. Email: imranyusufzai@gmail.com

^c BDS, MCPS-Periodontology, Smiline Dental Surgery Islamabad.

or a mixture of the two.¹³⁻¹⁴ Alloplastic material of hydroxyl apatite, tricalcium phosphate and xenografts are also used for bone augmentation and sinus lift procedures alone or in combination.¹⁵⁻¹⁶ This bone provides histologically and clinically compatible environment for primary stability of an implant that is functionally and aesthetically viable.¹⁷ Autografts have osteo-conductive and osteo-inductive properties and allografts have osteo-conductive properties. These properties play a role in the success of implant prosthesis.

Autogenous bone grafting has been considered as a gold standard for bone augmentation.¹⁸ Intraoral bone grafts have lesser bone resorption as compared to extra-oral sites.¹⁹ Although donor site morbidity is considered a limitation but that is also to a lesser extent when compared to extra-oral sites. Extra-oral sites for bone graft include iliac crest, calvarium and costochondral. Allografts can also be used for bone augmentation; however, that has its own benefits and limitations. Not having to open a donor site is considered to be a primary advantage, but the risk of cross infection does exist. There is a variety of choice in choosing graft materials, ranging from synthetic to cadaveric.²⁰ In the present study, allografts used were a mix of cancellous and cortical bone, grafted from cadavers.

Allografts and autografts combined are considered to be giving good results for bone augmentation as it induces osteogenic and osteoclastic activity necessary for bone remodelling.²¹ Combining allografts and autografts have been strongly advocated in sinus lift procedures as well.²² Bone graft has also been frequently advocated for immediate implant cases, particularly if a horizontal gap of 2 mm or more exists as postulated by Querynin et al.²³ Hence, bone graft allows a more predictable outcome for implant provision.

Material and Methods

This was a retrospective study of 107 patients undergoing bone grafts followed by an implant placement. There were three arms of our study. The first arm of patients receiving autografts (Group A, n=32). Group B consisted of patients that received allografts only predominantly from cadavers which was mixed cancellous and cortical bone (n=49). A third arm (Group C) in which mixed auto and allografts were used for bone augmentation (n 26).

The aim of the present study was to compare the success of implants in all three arms. 107 patients had bone grafts done with the intent of having implants placed. Our exclusion criterion included patients failing to turn up for follow up, flapless implants, implants used for overdentures, immediately loaded or progressively loaded implants, patients who had undergone bone grafting but have still not been provisioned with the implant fixture, patients not meeting the 6 month waiting time after implant placement into the grafted bone and patients who had received alloplasts as a graft material alone or in combination with autografts and/or allografts. Radiographic evidence of bone deposition was also evaluated. We compared success between these three arms.

Autografts can be used from intraoral and extraoral sites. Intraorally bone harvested during the osteotomy can be used otherwise trephine aspiration or grafts from anterior mandible or external oblique ridge can be used.^{7,10} Extra-orally grafts from iliac crest, calvarium or costochondral grafts can be used.^{7,10} Success was described as functionally and aesthetically compatible implants 6 months after placement of an implant/graft.²³

In all cases patients were medically assessed. They were consented for the procedure and informed of the risks of implant placement and bone grafts as well. The patients had

consented for the use of their statistical data for research and publication as well. Oral examination included periodontal assessment, assessment of the dentition and oral hygiene measures were reinforced where needed. Flaps were raised in all 107 implants. Simultaneous bone grafting with implant placement was carried out in 34 cases. Of these 9 cases were that of Group A, 22 of Group B and 3 of Group C. 73 patients had delayed implant placement which meant that we waited for the bone to be augmented at least 3 – 6 months before placing an implant. Out of 73 patients that received delayed implants, 23 were grafted with Autografts, 27 patients received an Allograft and rest 23 were grafted with combination of autografts and allografts. The mean time for this delay was 24.5 months in case of Group A, 6.3 months for Group B and 7.8 months for Group C. Major delay in the Group A was because these patients received extra oral grafts i.e. from iliac crest and hence two factors were seen before implant could be provisioned. First being absence of pathology and second; good uptake of the grafted bone before implants could be provisioned. The implants placed in all groups were of sizes 3.0 mm to 5.0 mm diameter, the mean being 3.82 and their lengths were of 8.0 mm to 12 mm, the mean being 10.8mm. These implants were not loaded for average 6.2 months time period. Our success criterion was primarily stable implants 6 months after insertion.

Results

A total of 107 implants were placed. A total of 32 implants were placed in bone where bone was augmented with an auto graft. The number of failures when evaluated according to our success criterion was one. The auto grafts were taken from osteotomy site, iliac crest and intra orally from distant site. Of the 49 implants were placed in bone augmented with an allograft and there were 4 failures. 26 implants were part of the mixed arm of which

there was 1 failure according to our success criterion. There was 1 failure in each of the implants when autograft was used alone or in combination. Hence, we are reporting 96.8% and 96.1% success respectively. We have a success rate of 91.8% when allograft was used alone, with 4 failures in 49 cases of group B. This establishes autograft as a gold standard for bone augmentation in dental implants. Yet allograft remains a popular choice

A total of 101 implants fulfilled the success criterion when they were placed following a bone graft procedure. Hence, we report 96.8% success of implants when autografts are used for bone augmentation alone and 96.1% when used in combination with allograft. The success rate of implants following an allograft alone is 91.8%. This success rate is below the success rate of agreed 97.0%.^{24,28} Not a single implant was placed with a flapless procedure. Implants were deemed successful if they met the criterion by albrektsson et al.²⁵

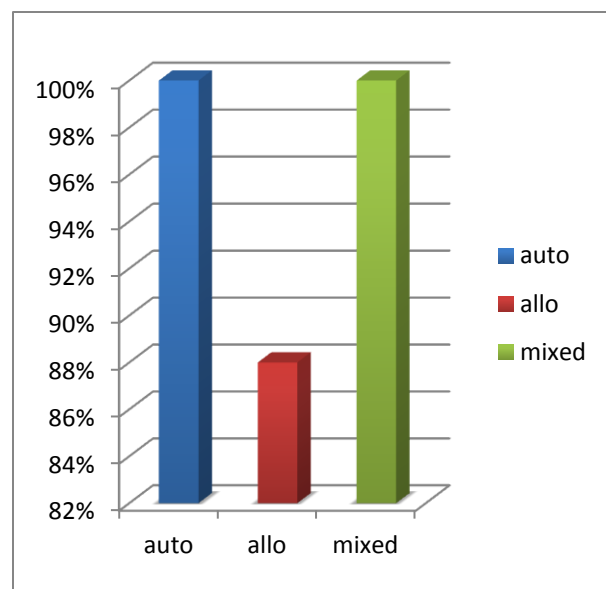


Figure 1: Showing Success % in Autografts, Allografts and Mixed Case

The patients with failures were non smokers, medically fit and well. It is of interest to note that there were smokers included in the cases where bone graft and provision of implant was successful. Primary stability was attained

at the time of their implant placement. Their periodontal health was assessed suitable for implant provision.

Discussion

It is of value to note that there has been only one failure in group A and group C. Autograft being the gold standard for placement of implants and a mix of autograft and allograft being the second best choice. Autografts not only present with minimum risk of cross infection but also has lesser chances of rejection. The disadvantage of having a second surgery site at the donor site is overwhelmed by the advantages. Although in medically compromised patients where minimal surgical intervention is the aim, allografts are of added advantage for this very reason. But allografts alone can only be used where minimal bone is needed.

It will be also of value to increase the sample size. Hence, we shall re-audit and carry out a larger study comparing these three arms. Longer follow up shall also be conducted and bone resorption around the implant shall be assessed. Resorption at a rate of 1.25 in the first year and to 0.1 to 0.2 mm annually is an acceptable rate²⁰ and anything in excess of this rate shall be looked into.

Where clinical situation allows, implant placement at the time of bonegraft had no adverse affect on the outcome as compared to delayed implant placement. Primary stability is the most important factor for osteointegration.²⁹ If primary stability can be attained, then the implant can be placed at the time of bone graft. The success of these implants can be reasonably predicted.

Assessment of implants stability shall be standardized and more and more tools shall be used. Instruments like frequency analyzer would be of value. Also histological analysis of bone quality can be of help and we aim to carry out a study in that regard.

Conclusions

It has been well established that the gold standard for bone augmentation for dental implants is the autografted bone. This bone may be grafted from an intra oral site or an extra oral site. There is minimal difference in the success of the intraoral and extra oral grafts. The outcome can be predicted with reasonable success.

We agree that an autograft may not always be available in enough quantity due to multiple reasons ranging from the medical status of the patient to the quantity and quality of bone needed, to operators comfort with harvesting an extra oral graft. In these cases a mixture of allograft and auto graft can be considered the second best choice for bone augmentation.

Allograft being a very commonly used graft for bone augmentation for dental implants shall be used with caution and better alternates shall always be sought first and there shall be clinical and scientific reason for not using better alternatives like autograft or a mixture of autografts and allografts. Allografts do have the added advantage of limiting surgical sites; therefore, it is of value in medically compromised patients where the clinical scenario allows placing an implant with just an allograft. This is usually in situations where minimal bone is needed.

Implants can be placed at the time of the bone graft provided primary stability is achievable. Immediately placed implants at the time of bone graft had no changes in the success rates as opposed to delayed placed implants. This also reduces the number of surgeries and edentulous time period for the patient.

Hence, autografts that might be intraoral or extraoral shall be the preferred graft for bone augmentation for dental implants. Autograft combined with allografts shall be the second preferred choice. This is by virtue of the osteoconductive and osteoinductive properties retained in the graft material.³⁰ Implants can be placed simultaneously at the time of bone graft, provided primary stability is attained.

References

1. Monje A, Monje F, Suarez F, Gonzalez-Garcia R, Villanueva-Alcojol L, Garcia-Nogales A, et al. Comparison of implant primary stability between maxillary edentulous ridges receiving intramembranous origin block grafts. *Med Oral Patol Oral Cir Bucal* 2013;18(3):e449-54.
2. Albrektsson T, Zarb GA. Current interpretations of the osseointegrated response: clinical significance. *Int J Prosthodont* 1993;6(2):95-105.
3. Merheb J, Quirynen M, Teughels W. Critical buccal bone dimensions along implants. *Periodontol* 2000 2014;66(1):97-105.
4. Shanaman RH. A retrospective study of 237 sites treated consecutively with guided tissue regeneration. *Int J Periodontics Restorative Dent* 1994;14(4):292-301.
5. Nevins M, Mellonig JT. Enhancement of the damaged edentulous ridge to receive dental implants: a combination of allograft and the GORE-TEX membrane. *Int J Periodontics Restorative Dent* 1992;12(2):96-111.
6. Fugazzotto PA. Report of 302 consecutive ridge augmentation procedures: technical considerations and clinical results. *Int J Oral Maxillofac Implants* 1998;13(3):358-68.
7. Keller EE, Eckert SE, Tolman DE. Maxillary antral and nasal one-stage inlay composite bone graft: preliminary report on 30 recipient sites. *J Oral Maxillofac Surg* 1994;52(5):438-47; discussion 47-8.
8. Kent JN, Block MS. Simultaneous maxillary sinus floor bone grafting and placement of hydroxylapatite-coated implants. *J Oral Maxillofac Surg* 1989;47(3):238-42.
9. Jensen J, Simonsen EK, Sindet-Pedersen S. Reconstruction of the severely resorbed maxilla with bone grafting and osseointegrated implants: a preliminary report. *J Oral Maxillofac Surg* 1990;48(1):27-32.
10. Williamson RA. Rehabilitation of the resorbed maxilla and mandible using autogenous bone grafts and osseointegrated implants. *Int J Oral Maxillofac Implants* 1996;11(4):476-88.
11. Boyne PJ, James RA. Grafting of the maxillary sinus floor with autogenous marrow and bone. *J Oral Surg* 1980;38(8):613-6.
12. Frost DE, Fonseca RJ, Burkes EJ, Jr. Healing of interpositional allogeneic lyophilized bone grafts following total maxillary osteotomy. *J Oral Maxillofac Surg* 1982;40(12):776-86.
13. Wetzel AC, Stich H, Caffesse RG. Bone apposition onto oral implants in the sinus area filled with different grafting materials. A histological study in beagle dogs. *Clin Oral Implants Res* 1995;6(3):155-63.
14. Tidwell JK, Blijdorp PA, Stoelinga PJ, Brouns JB, Hinderks F. Composite grafting of the maxillary sinus for placement of endosteal implants. A preliminary report of 48 patients. *Int J Oral Maxillofac Surg* 1992;21(4):204-9.
15. Smiler DG, Johnson PW, Lozada JL, Misch C, Rosenlicht JL, Tatum OH, Jr., et al. Sinus lift grafts and endosseous implants. Treatment of the atrophic posterior maxilla. *Dent Clin North Am* 1992;36(1):151-86; discussion 87-8.
16. Fugazzotto PA. Maxillary sinus grafting with and without simultaneous implant placement: technical considerations and case reports. *Int J Periodontics Restorative Dent* 1994;14(6):544-51.
17. Jacotti M, Wang HL, Fu JH, Zamboni G, Bernardello F. Ridge augmentation with mineralized block allografts: clinical and histological evaluation of 8 cases treated with the 3-dimensional block technique. *Implant Dent* 2012;21(6):444-8.
18. Tessier P, Kawamoto H, Matthews D, Posnick J, Raulo Y, Tulasne JF, et al. Autogenous bone grafts and bone substitutes--tools and techniques: I. A 20,000-case experience in maxillofacial and craniofacial surgery. *Plast Reconstr Surg* 2005;116(5 Suppl):6S-24S; discussion 92S-94S.
19. Zins JE, Whitaker LA. Membranous versus endochondral bone: implications for craniofacial reconstruction. *Plast Reconstr Surg* 1983;72(6):778-85.
20. Clementini M, Morlupi A, Agrestini C, Ottria L. Success rate of dental implants inserted in autologous bone graft regenerated areas: a systematic review. *Oral Implantol (Rome)* 2011;4(3-4):3-10.
21. Veron C, Chanavaz M, Ferri J, Donazzan M, Hildebrand HF. [A panorama of current materials for osseous application in maxillofacial surgery and oral implantology]. *Rev Stomatol Chir Maxillofac* 1995;96(4):274-81.
22. Beretta M, Poli PP, Grossi GB, Pieroni S, Maiorana C. Long-term survival rate of implants placed in conjunction with 246 sinus floor elevation procedures: Results of a 15-year retrospective study. *J Dent* 2014.
23. Quirynen M, Van Assche N, Botticelli D, Berglundh T. How does the timing of implant placement to extraction affect outcome? *Int J Oral Maxillofac Implants* 2007;22 Suppl:203-23.
24. Hurzeler MB, Kirsch A, Ackermann KL, Quinones CR. Reconstruction of the severely resorbed maxilla with dental implants in the augmented maxillary sinus: a 5-year clinical investigation. *Int J Oral Maxillofac Implants* 1996;11(4):466-75.
25. Albrektsson T, Zarb G, Worthington P, Eriksson AR. The long-term efficacy of currently used dental implants: a review and proposed criteria of success. *Int J Oral Maxillofac Implants* 1986;1(1):11-25.

26. Albrektsson T, Dahl E, Enbom L, Engevall S, Engquist B, Eriksson AR, et al. Osseointegrated oral implants. A Swedish multicenter study of 8139 consecutively inserted Nobelpharma implants. *J Periodontol* 1988;59(5):287-96.
27. Adell R, Eriksson B, Lekholm U, Branemark PI, Jemt T. Long-term follow-up study of osseointegrated implants in the treatment of totally edentulous jaws. *Int J Oral Maxillofac Implants* 1990;5(4):347-59.
28. Fugazzotto PA, Gulbransen HJ, Wheeler SL, Lindsay JA. The use of IMZ osseointegrated implants in partially and completely edentulous patients: success and failure rates of 2,023 implant cylinders up to 60+ months in function. *Int J Oral Maxillofac Implants* 1993;8(6):617-21.
29. Sennerby L, Roos J. Surgical determinants of clinical success of osseointegrated oral implants: a review of the literature. *Int J Prosthodont* 1998;11(5):408-20.
30. Gomes KU, Carlini JL, Biron C, Rapoport A, Dedivitis RA. Use of allogeneic bone graft in maxillary reconstruction for installation of dental implants. *J Oral Maxillofac Surg* 2008;66(11):2335-8.