

FREQUENCY OF ROOT RESORPTION AFTER FIRST SIX MONTHS OF ACTIVE ORTHODONTIC TREATMENT

Dr. Ambreen Afzal Ehsan ^a, Dr.Samreen Iqtadar ^b

^a B.D.S., F.C.P.S. (Pak), C-Ortho, O.F.O.S. (USA), F.T.M.J.(N.Y.U.). Dean of Academics / Vice principal, Head of Orthodontics Dept. Altamash Institute of Dental Medicine.

^b BDS, FCPS – II trainee, Department of Orthodontics, Altamash Institute of Dental Medicine, Karachi.

ABSTRACT

Introduction: External apical root resorption is a common clinical complication of orthodontic treatment, characterized by permanent shortening of the end of the tooth root that can be seen on routine dental radiographs. Root resorption can be detected on radiographs after initial 5-6 months of orthodontic treatment. This study was aimed to determine the frequency of root resorption of maxillary incisors and mandibular incisors after the first six months of orthodontic treatment. **Material and Methods:** This Quasi-experimental study was carried out at Department of Orthodontics, Altamash Institute of Dental Medicine, Karachi. Non-probability purposive sampling technique was used. Eighty five patients with age ranging from 18 – 25 years were selected. Periapical radiographs, using paralleling technique were taken before the start of treatment and at the end of the study period (after 6 months) and inciso-apical length of all the incisors were measured using vernier caliper. **Results:** In upper incisors, 47 patients showed minimal root resorption, 32 patients showed acceptable while 6 patients showed non acceptable root resorption. In lower incisors, 42 patients showed minimal, 37 patients showed acceptable and 6 patients showed non acceptable root resorption. Significant association between age and resorption was seen in upper and lower incisors **Conclusion:** Root resorption can be observed during the early stages of orthodontic treatment. More root resorption was seen in patients above 21 years of age, while greater number of patients between 17- 20 years of age showed level 2 of root resorption in their upper and lower incisors.

Key words: External Apical root resorption, Root resorption, Orthodontic tooth movement, Maxillary and mandibular incisors.

Correspondence: . Prof Ambreen Afzal Ehsan, Department Of Orthodontics, Altamash Institute Of Dental Medicine, Karachi, email: drafzal@msn.com

INTRODUCTION

Root resorption is the most undesirable and iatrogenic sequelae of the orthodontic treatment. ^{1,2} Root resorption is a physiologic or a pathologic process resulting in the loss of cementum and dentine and it can be classified as external (Illustration -1) and internal (Illustration -2). Root resorption relating to orthodontics is external apical root resorption (EARR).^{3,4} External apical root resorption (EARR)

has been defined as a reduction in the length of the root from the apex.⁵ EARR is initiated within 35 (14 to 20) days after orthodontic force is applied and may continue for the duration of force application.^{6, 7, 8} EARR occurs during treatment when forces at the apex exceed the resistance and reparative ability of the periapical tissues.⁹

The term orthodontically induced inflammatory root resorption (OIRR) proposed by Brezniak and Wasserstein was defined as a sterile inflammatory process that is extremely complex and composed of various disparate components including forces, tooth roots, bone, cells, surrounding matrix, and certain known biological messengers.¹⁰

OIRR leads to an ischemic necrosis that is localized in the periodontal ligament when the orthodontic force is applied.^{1,11} OIRR differs from other kinds of resorption because this is a sterile, local inflammatory process, which is complicated and has all characteristic inflammatory symptoms.¹²

During orthodontic tooth movement compression sites are more at a risk of root resorption than tension sites.¹³ External apical root resorption can begin in the early leveling and alignment stages of orthodontic treatment.¹⁴ The arch wires used during this phase have a strong correlation with local necrosis and apical root resorption.^{15, 16, 17} Typical tooth movements during initial leveling are in the form of crown tipping rather than root movement.¹⁵

The prevalence among the researches varies widely. Means values ranging from 0.5 to 3 mm of root shortening during treatment have been reported. A frequency of severe apical root resorption of 5-18% has been reported. Killiany reported root resorption of > 3 mm to occur at a frequency of 30%, with only 5% of treated individuals found to have > 5 mm of root resorption.

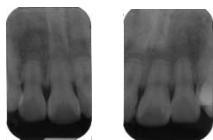


ILLUSTRATION – 1

Periapical Radiographs Of Upper Incisors Showing EARR

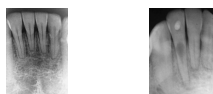

ILLUSTRATION – 2
Periapical Radiographs Of Lower Incisors Showing EARR & IARR

Resorption occurs primarily in the maxillary anterior teeth, averaging over 1.4 mm. The worst resorption is seen in maxillary lateral incisors.¹⁴ While molars seems to be least affected.² Studies have shown that 20.2% - 33.2% of incisors experience 2mm or more root resorption when exposed to orthodontic forces.¹⁶ The etiology of root resorption is multifactorial.⁶ The onset and progression of root resorption are associated with risk factors, both biologic and mechanical factors. Mechanical factors are the treatment associated factors, for instance, duration of treatment, the magnitude of force applied, direction and type of tooth movement, appliance used and the method of force application (continuous versus intermittent).

Biological factors are the patient related risk factors which include, individual susceptibility, races, genetics, nutrition, chronological age, gender, malocclusion type and severity, systemic diseases, habits, anomalies in root morphology, dental trauma, dense alveolar bone and previous endodontic treatment.¹⁸⁻²⁰

Most orthodontic patients experience some degree of root resorption.²¹ In most instances, this phenomenon is clinically asymptomatic.²² Fortunately, it is very rare that root resorption is severe enough to create a clinical problem, and the benefits of esthetic and functional corrections of orthodontics far outweigh these normally minor side effects, however, in a small percentage of patients (5 – 10%) the degree of resorption exceeds acceptable levels and the longevity of the affected teeth may be compromised.²¹

The detection of root resorption has been mainly through radiographs, light microscopy and scanning electron microscopy (SEM).^{23, 24} Radiographs are clinically relevant in detecting root shortening before, during or after orthodontic treatment.²³ Periapical radiographs are much superior to the panoramic,

occlusal, and the lateral cephalometric radiographs for studying root structures, primarily when obtained with the long cone paralleling technique.²⁵ Root resorption can be detected in the early stages of orthodontic treatment.^{17, 26} A reliable radiographic diagnosis of apical root resorption can be performed after 5 -6 months of initiation of orthodontic treatment.¹¹ Early detection of root resorption during orthodontic treatment is essential for identifying teeth at risk of severe resorption.²

The aim of this study is to quantify the root resorption after first six months of orthodontic treatment at Altamash Institute Of Dental Medicine, Karachi.

MATERIAL AND METHODS:

This Quasi-experimental study was carried out at Department of Orthodontics, Altamash Institute of Dental Medicine, Karachi. Non-probability purposive sampling technique was used. Sample consists of eighty five patients, with age ranging from 13 – 25 years were selected.

INCLUSION CRITERIA:

- Male and female subjects between 13- 25 years of age who came to seek fixed orthodontic treatment at Altamash Institute Of Dental Medicine, Karachi.

EXCLUSION CRITERIA:

- Patients with history of previous orthodontic treatment.
- Patients with abnormal shape and incomplete root formation.
- Teeth with debondings of the brackets in the middle of the treatment.
- Patients suffering from systemic diseases, asthma, diabetes mellitus, hormonal imbalances, endocrine problems and metabolic derangements.
- Patients with advance periodontal diseases (gingivitis, periodontitis).

- Craniofacial malformations and syndromes.

DATA COLLECTION PROCEDURE:

Data was collected from the patients coming to the (OPD) of orthodontic clinics of Altamash Institute Of Dental Medicine. The first 85 patients who satisfy the inclusion criteria and provide consent for the study were selected, irrespective of their malocclusion group. Periapical radiographs of maxillary incisors (12, 11, 21 & 22) and mandibular incisors (42, 41, 31 & 32) using paralleling technique with XCP cone indicator were taken before the start of the treatment. The film packet is placed in a holder and positioned parallel to the teeth under investigation. The X-ray tube head is then placed at right angles to both the teeth and film packet. The incisio- apical length (TL1) of all the incisors were measured (in mm) and recorded. Tooth length was measured as the distance from the tip of the apex to the mid point of the incisal edge. All the measurements were obtained using vernier caliper to get closest reading one place after the decimal. At the end of the study period (after six months), Periapical radiographs of maxillary incisors (12, 11, 21 & 22) and mandibular incisors (42, 41, 31 & 32) using paralleling technique with XCP cone indicator were repeated and the root length (TL2) of incisors were measured again using the same technique. Decrease in root length \geq 2mm was considered as resorption. All the readings were subjected to statistical analysis.

RESULTS

There were 85 patients in our study. Minimum patient's age was 13 years and maximum age was 25 years with a mean age of 18.76 years and standard deviation of 3.66 (Table I). Male to female ratio was 2:3 (Fig I). The age and gender distribution can be seen in Table 2. In upper incisors, 47 patients showed minimal root resorption, 32 patients showed acceptable root resorption and 6 patients showed non acceptable root

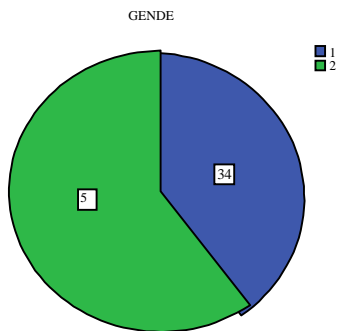
Table 1
Descriptive statistics of age
N= 85

Min	Max	Mean	sd
13	25	18.76	3.660

Significant association between age and root resorption was seen. More root resorption was seen in patients above 21 years of age in both upper and lower incisors. While greater number of patients with level 2 resorption was observed in 17-20 years age category. Level of significance (p-value) is 0.021 for upper incisors (Table 3) and 0.032 for lower incisors (Table 4).

Figure 1

DISTRIBUTION OF GENDER
n=85



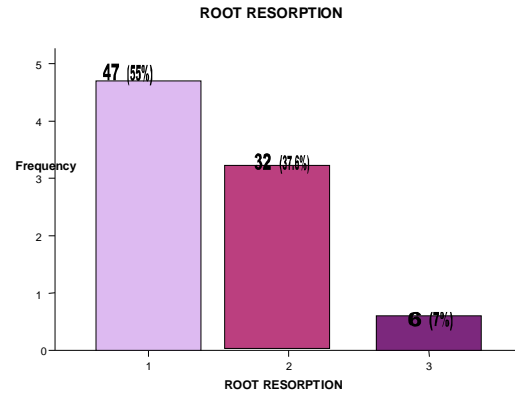
Legends:
1: male
2: female

Table 2
Distribution of age and gender

		Male	Female	Total
Age	13-16 yr	11	16	27
	17-20 yr	12	17	29
	>21 yr	11	18	29
Total		34	51	85

Figure 2

Distribution of root resorption in upper incisors

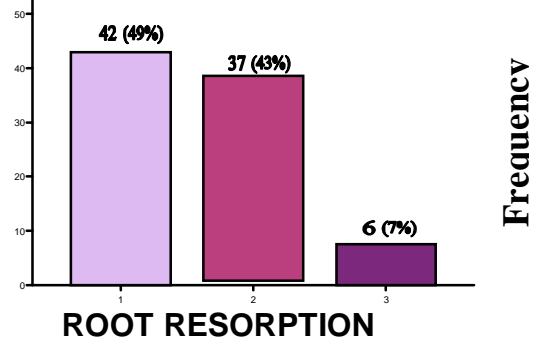


Legend:

- 1: Up to 1mm resorption
- 2: 1-2 mm resorption
- 3: more than 2mm resorption

Figure 3

Distribution of resorption in lower incisors



Legend:

- 1: Up to 1mm resorption
- 2: 1-2 mm resorption
- 3: more than 2mm resorption

Table 3

Association between age and root resorption in upper incisors

		Root Resorption in upper incisors			Total	p-value
		Level 1 (0-1mm)	Level 2 (1-2mm)	Level 3 (>2mm)		
AGE	13-16 yr	18	8	1	27	0.021
	17-20 yr	13	16	0	29	
	>21 yr	16	8	5	29	
	Total	47	32	6	85	

Test of significance: Chi Square

Level of significance 0.05

Significant association between age and root resorption is seen

DISCUSSION

Root resorption is an undesirable sequel of orthodontic treatment and remains a common

Table 4

Root Resorption in Lower Incisors				Total	p-value
Age	Level 1 (0-1mm)	Level 2 (1-2mm)	Level 3 (≥2mm)		
13-16 yr	14	12	1	27	0.032
17-20 yr	12	17	0	29	
>21 yr	16	8	5	29	
Total	42	37	6	85	

Association between age and root resorption in lower incisors

Test of significance: Chi Square

Level of significance 0.05

Significant association between age and root resorption is seen

iatrogenic problem in orthodontics.^{3, 4} There are primarily two impediments to preventing resorption:

- (1) Root apices are prone to resorption when the periodontium is compressed, so teeth cannot be moved through bone without producing some odontoclasia, and
- (2) No exact criteria have been found that predict which patients will experience overt resorption and which will exhibit little under the same treatment regimens and the esthetic and functional benefits of treatment outweigh the minor iatrogenic sequelae.³

Root resorption is a multifactorial phenomenon and many studies have analyzed the suspected causes of EARR. Research has shown that root resorption can occur in the early leveling stages of orthodontic treatment.^{4, 15, 27}

Smale et al. reported that root resorption can be detected even in the early stages of orthodontic treatment and teeth with long, narrow and deviated

roots are at increased risk of resorption during this early stage.^{8, 17, 28}

Minor OITRR in the first 6 months is a strong indicator of progressive root resorption by the end of orthodontic treatment. Progressive OITRR can lead to a compromised crown to root ratio and compromised function.^{15, 27}

We can detect OIRR after first six months of orthodontic treatment on the periapical radiographs. We proposed that using periapical radiographs with standardized paralleling technique is an effective modality for detecting root resorption during orthodontic treatment with less radiation exposure and is cost effective. The literature agrees that abnormal root shape and jiggling forces increases the risk of the orthodontically induced inflammatory root resorption. It is therefore suggested to proceed with the early leveling stages of orthodontic treatment with caution.^{4, 29}

The aim of this study was to determine the frequency of root resorption of maxillary and mandibular incisors after the first six months of orthodontic treatment. We confirmed the findings of Levander and Malmgren that most orthodontic patients develop visible signs of apical root resorption of the maxillary and mandibular incisors during the initial stages of fixed appliance therapy. However, the resorption is typically expressed only as a slight change in apical contour without actual root shortening.^{15, 30}

Maxillary and mandibular anterior teeth were selected for the study because apical root resorption occurs mainly in the anterior teeth. Studies reveal that maxillary incisors are most susceptible to the iatrogenic consequences of orthodontic forces,³¹⁻³⁵ and are the first teeth to respond when subjected to fixed appliance activation.³⁶ Janson et al (2000), reported that the upper central incisors showed more root resorption than the upper lateral incisors, while others found the opposite.^{25, 26, 35, 37} Research data

suggests that maxillary teeth are more susceptible to root resorption than the mandibular teeth because these teeth are subjected to greater movements with their root structure and relationship to bone tending to transfer the forces mainly to the apex. DeSheilds suggested that if there is no resorption of upper and lower incisors than significant resorption in other teeth is less likely to occur. Other researches have shown that root resorption is more common in mandibular incisors.³⁸

In this study the patients were selected based upon the previously discussed criteria. Patients were not accepted into the sample if they had undergone any previous orthodontic treatment including growth modification, maxillary expansion or orthognathic surgery. Maxillary expansion was excluded because expansion itself has been shown to cause root resorption (buccal surface and furcation area) and the resorption detected may be the result of expansion rather than the fixed orthodontic treatment.³⁹

Orthognathic surgery cases that have had maxillary surgery have been shown to demonstrate an increased risk of root resorption and were excluded.⁴⁰ There is a high correlation between the amount and severity of root resorption present before treatment, to the resorption discovered after six months of initiation of fixed orthodontic treatment. Therefore patients who had previous orthodontic treatment may have had resorption and were excluded.

Other predisposing factors of root resorption, which led to exclusion, were trauma and root canal therapy. Patients were excluded if there was any incisal adjustment as this would change the physical length of the teeth and also the trauma to the tooth may potentially cause greater resorption.

All patients who had systemic problems (asthma and endocrine problems such as hypothyroidism, hyperpituitarism, hypophosphatemia and Paget's

disease and others) were excluded as these conditions have been linked to root resorption.

Any patients with impacted teeth were excluded, as there is an increased incidence of root resorption of the adjacent teeth. It has been shown that ectopically erupting maxillary canine cause some degree of resorption of adjacent incisors (0.7%) in the 10-13 year age group.^{41, 42}

In this study, we selected 85 patients aged between 13- 25 years, minimum age of 13 years was chosen to exclude the undesirable effect of residual root growth.⁴¹ Rosenberg has stated that teeth with incomplete root formation undergo less root resorption than those with completely formed roots. It is stated that incompletely formed roots reach their normal root length. Naphtali Brezniak et al. have stated that if tooth root are not completely formed in the beginning of orthodontic treatment, they are further developing during treatment, however remain shorter.^{10, 12}

By this age apexogenesis of maxillary and mandibular incisors would be completed and the teeth would not get longer during treatment due to further root growth. Any lengthening could then be assumed to be due to magnification or measurement errors.⁴³

The higher age limit of 25 years was chosen in order to eliminate the unfavorable effect of age that may lead to increased EARR due to creation of more hyalinized areas, longer hyalinization duration, and lower healing activity in adults.^{29, 32, 44} There is a possibility that the older patients may experienced more root resorption as, periodontal membrane becomes narrower and less vascularized, aplastic, alveolar bone becomes denser and cementum becomes wider with age.^{42, 45, 46}

Previous data suggests, that adults have been reported to be more susceptible to root resorption. However the traditional belief that orthodontic root resorption

increases with age was recently disproved.^{20, 31, 41, 47, 48-52} Sameshima and Sinclair (2001) found that adult patients experienced more root resorption than children in mandibular anterior segment only.^{21, 53}

All recent studies with the exception of two studies have found no relationship between OIIRR and chronological age, which suggests, chronological age may not be a significant factor in the occurrence of OIIRR.^{1, 10, 34, 42, 51-55}

The significant association between age and root resorption was found in our study. More root resorption is seen in patients above 21 years of age in both upper and lower incisors, while greater number of patients with level-2 resorption (b/w 1-2mm) was observed among 17-20 year age group.

The frequency of root resorption observed during the initial six month period in our study reveals, that 55% patients showed minimal root resorption of up to 1mm, 37.6% patients showed acceptable root resorption b/w 1-2mm and 7% of patients showed non acceptable root resorption of more than 2mm in upper incisors during the first six months of orthodontic treatment (Fig 2). In lower incisors, 49% patients showed minimal root resorption of up to 1mm, 43% showed acceptable root resorption b/w 1-2mm and 7% patients showed non acceptable root resorption of more than 2mm during the first six months of orthodontic treatment (Fig 3). In keeping with previous studies, we found that apical root resorption is a minor problem for the average orthodontic patients, and only few patients are severely affected. However, we failed to find the previously documented difference in amount of resorption between the central and lateral incisors.

Root resorption associated with orthodontic treatment usually stop after completion of active orthodontic treatment. Active root resorption lasts approximately about a week after removal of orthodontic appliance. Cementum repair lasts 5-6 weeks after removal of

orthodontic appliance. Root resorption after removal of orthodontic appliances is mostly related to causes such as occlusal trauma, active retainers or others.^{12, 32}

We highly recommend taking progress periapical radiographs a few months after active tooth movement for patients at risk. If root resorption is found, the literature supports an inactive phase of 4 to 6 months before the resumption of treatment. In extreme cases, treatment must be halted appliances must be removed, and a surgical or prosthetic treatment plan must be adopted.²⁶

LIMITATIONS OF THE STUDY:

Root resorption is a 3D phenomenon, and its extent must be quantified with precision. Periapical radiographs used for detection of root resorption are technique sensitive and can detect resorption only after 60–70% of the mineralized tissue is lost.² They only provide two-dimensional information primarily identifying apical change. Radiographs cannot indicate if the process of root resorption is still active. Monitoring the progress of root resorption requires additional radiation exposure to the patient. Magnification errors might lead to underestimation or overestimation of the amount of root resorption.⁵

The initial resorption lacunae are small and can be identified only by histologic or scanning electron microscopy studies, but these are performed on experimentally moved and then extracted premolars.⁵⁶⁻⁵⁸

For this study we have decided to consider decrease in root length of ≥ 2 mm as root resorption. Only 6 patients above 21 years of age out of 85, showed non acceptable root resorption of > 2 mm in upper and lower incisors respectively. We were also not able to observe level 3 resorption (≥ 2 mm) among patients below 21 years. These limitations can be attributed to small sample size and duration of the study.

CONCLUSIONS

1. Root resorption can begin in the early stages of orthodontic treatment.
2. The age was associated with root resorption in both upper and lower incisors. More of the level 3 root resorption was observed in patients above 21 years of age. While greater number of patients, between 17- 20 years of age showed level 2 of root resorption in their upper and lower incisors.

REFERENCES:

1. Pizzo G, Licata ME, Guiglia R, Giuliani G. Root resorption and orthodontic treatment. Review of the literature. *Minerva Stomatol.* 2007;56(1-2):31-44.
2. Balducci L, Ramachandran A, Hao J, Narayanan K, Evans C, George A. Biological markers for evaluation of root resorption. *Arch Oral Biol.* 2007; 52(3):203-8.
3. Parker RJ, Harris EF. Directions of orthodontic tooth movements associated with external apical root resorption of the maxillary central incisor. *Am J Orthod Dentofacial Orthop.* 1998;114(6):677-83.
4. Kitahara T, Takashima R, Nakasima A, Kurahara S. Orthognathic treatment case after severe root resorption in the early treatment stage. *Orthod Waves.* 2009;68(1):28– 35.
5. Eraso FE, Parks ET, Roberts WE, Hohlt WF, Ofner S. Density value means in the evaluation of external apical root resorption: an in vitro study for early detection in orthodontic case simulations. *Dentomaxillofac Radiol.* 2007;36(3):130–7.
6. Ramanathan C, Hofman Z. Root resorption in relation to orthodontic tooth movement. *Acta medica (hradec králové).* 2006;49(2):91–5.
7. El-Bialy T, El-Shamy I, Graber TM. Repair of orthodontically induced root resorption by ultrasound in humans. *Am J Orthod Dentofacial Orthop.* 2004;126(2):186-93.
8. Wierzbicki T, El-Bialy T, Aldaghreer S, Li G, Doschak M. Analysis of Orthodontically Induced Root Resorption Using Micro-Computed Tomography (Micro-CT). *Angle Orthod.* 2009;79(1):91–6.
9. Parker RJ, Harris EF. Directions of orthodontic tooth movements associated with external apical root resorption of the maxillary central incisor. *Am J Orthod Dentofacial Orthop.* 1998;114(6):677-83.
10. Brezniak N, Wasserstein A. Orthodontically induced inflammatory root resorption. Part II: The clinical aspects. *Angle Orthod.* 2002;72(2):180-4.
11. Filho PF, Letra A, Carvalhal JC, Menezes R. Orthodontically induced inflammatory root resorptions: a case report. *Dent Traumatol.* 2006;22(6):350-3.
12. Lopatiene K, Dumbravaite A. Risk factors of root resorption after orthodontic Treatment. *Stomatologija.* 2008;10(3):89-95.
13. Gu G, Lemery SA, King GJ. Effect of appliance reactivation after decay of initial activation on osteoclasts, tooth movement, and root resorption. *Angle Orthod.* 1999;69(6):515-22.
14. Abuabara.A. Biomechanical aspects of external root resorption in orthodontic therapy. *Med Oral Patol Oral Cir Bucal.* 2007;12(8):610-3.
15. Smale I, Artun J, Behbehani F, Doppel D, van't Hof M, Kuijpers-Jagtman AM. Apical root resorption 6 months after initiation of fixed orthodontic appliance therapy. *Am J Orthod Dentofacial Orthop.* 2005;128(1):57-67.
16. Artun J, Smale I, Behbehani F, Doppel D, van't Hof M, Kuijpers-Jagtman AM. Apical root resorption six and twelve months after initiation of fixed orthodontic appliance therapy. *Angle Orthod.* 2005;75(6):919–26.

17. Fuck LM, Drescher D. Force systems in the initial phase of orthodontic treatment – a comparison of different leveling archwires. *J Orofac Orthop.* 2006;67(1):6-18.
18. Vlaskalic V, Boyd RL, Baumrind S. Etiology and sequelae of root resorption. *Semin Orthod.* 1998;4(2):124-31.
19. Armstrong D, Kharbanda OP, Petocz P, Darendeliler MA. Root resorption after orthodontic treatment. *Aust Orthod J.* 2006;22(2):153-60.
20. Nigul K, Jagomagi T. Factors related to apical root resorption of maxillary incisors in orthodontic patients. *Stomatologija.* 2006;8(3):76-9.
21. Anchalee P. The extent of root resorption after the application of continuous and controlled orthodontic forces for 12 weeks: A micro CT scan study. (Thesis), Australia: university of Sydney; [Online]. 2007 [cited 2007 Feb 8]; Available from: URL:<http://ses.library.usyd.edu.au/handle/2123/4287>
22. Brezniak N, Goren S, Zoizner R, Dinbar A, Arad A, Wasserstein A, Heller M. A Comparison of Three Methods to Accurately Measure Root Length. *Angle Orthod.* 2004;74(6):786-91.
23. Chan EK, Darendeliler MA. Exploring the third dimension in root resorption. *Orthod Craniofac Res.* 2004;7(2):64-70.
24. Chan EK, Petocz P, Darendeliler MA. Validation of two-dimensional measurements of root resorption craters on human premolars after 28 days of force application. *Eur J Orthod.* 2005;27(4):390-5.
25. Janson GR, De Luca Canto G, Martins DR, Henriques JF, De Freitas MR. A radiographic comparison of apical root resorption after orthodontic treatment with 3 different fixed appliance techniques. *Am J Orthod Dentofacial Orthop.* 2000;118(3):262-73.
26. Sameshima GT, Sinclair PM. Predicting and preventing root resorption: Part II. Treatment factors. *Am J Orthod Dentofacial Orthop.* 2001;119(5):511–5.
27. Huang Y, Wang XX, Zhang J, Liu C. Root Shortening in Patients Treated with Two-step and En Masse Space Closure Procedures with Sliding Mechanics. *Angle Orthod.* 2010;80(3):492-7.
28. Krishnan V. Critical issues concerning root resorption: a contemporary review. *World J Orthod.* 2005;6(1):30–40.
29. Mirabella AD, Artun J. Risk factors for apical root resorption of maxillary anterior teeth in adult orthodontic patients. *Am J Orthod Dentofacial Orthop.* 1995;108(1):48-55.
30. Levander E, Malmgren O. Evaluation of the risk of root resorption during orthodontic treatment: a study of upper incisors. *Eur J Orthod.* 1988; 10(1):30-8.
31. Sameshima GT, Sinclair PM. Predicting and preventing root resorption: Part I. Diagnostic factors. *Am J Orthod Dentofacial Orthop.* 2001;119(5):505–10.
32. Brezniak N, Wasserstein A. Root resorption after orthodontic treatment: Parts I and II. Literature review. *Am J Orthod Dentofacial Orthop.* 1993;103(2):62-6,138-46.
33. Van Loenen M, Dermaut LR, Degrieck J, De Pauw GA. Apical root resorption of upper incisors during the torquing stage of the tip-edge technique. *Eur J Orthod.* 2007;29(6):583-8.
34. Costopulos G, Nanda R. An evaluation of root resorption incident to orthodontic intrusion. *Am J Orthod Dentofacial Orthop.* 1996;109(5):543-8.
35. Blake M, Woodside DG, Pharoah MJ. A radiographic comparison of apical root resorption after orthodontic treatment with the edgewise and speed appliances. *Am J Orthod Dentofacial Orthop.* 1995;108(1):76-84.

36. Apajalahti S, Peltola JS. Apical root resorption after orthodontic treatment- a retrospective study. *Eur J Orthod.* 2007;29(4):408-12.
37. Harris EF. Root resorption during orthodontic therapy. *Semin Orthod.* 2000;6(3):183-194.
38. Armstrong D. A radiographic analysis of apical root resorption after orthodontic treatment with straight wire, speed and tip edge appliances. (Thesis), Australia: University of Sydney. [Online]; 2007 [cited 2007 Feb 4]; Available from; URL: <http://ses.library.usyd.edu.au/bitstream/2123/4190/1/0057.pdf>.
39. Vardimon AD, Graber TM, Voss LR, Lenke J. Determinants controlling iatrogenic root resorption and repair during and after palatal expansion. *Angle Orthod.* 1991;61(2):113-24.
40. Kaley J, Phillips C. Factors related to root resorption in edgewise practice. *Angle Orthod.* 1991;61(2):125-32.
41. Linge L, Linge BO. Patient characteristics and treatment variables associated with apical root resorption during orthodontic treatment. *Am J Orthod Dentofacial Orthop.* 1991; 99(1):35-43.
42. Brin I, Ben- Bassat Y, Heling I, Engelberg A. The influence of orthodontic treatment on previously traumatized permanent incisors. *Eur J Orthod.* 1991;13(5):372-7.
43. Brin I, Tulloch JF, Koroluk L, Philips C. External apical root resorption in Class II malocclusion: A retrospective review of 1-versus 2-phase treatment. *Am J Orthod Dentofacial Orthop.* 2003;124(2):151-6.
44. Harris EF, Baker WC. Loss of root length and crestal bone height before and during treatment in adolescent and adult orthodontic patients. *Am J Orthod Dentofacial Orthop.* 1990;98(5):463-9.
45. Travess H, Roberts-Harry D, Sandy J. Orthodontics. Part 6: Risks in orthodontic treatment. *Br Dent J.* 2004;196(2):71-7.
46. Luther F, Dominguez-Gonzalez S, Fayle SA. Teamwork in orthodontics: limiting the risks of root resorption. *Br Dent J.* 2005;198(7):407-11.
47. Beck BW, Harris EF. Apical root resorption in orthodontically treated subjects: Analysis of edgewise and light wire mechanics. *Am J Orthod Dentofacial Orthop.* 1994;105:350-61.
48. Otis LL, Hong JSH, Tuncay OC. Bone structure effect on root resorption. *Orthod Craniofacial Res.* 2004;7(3):165-77.
49. Baumrind S, Korn EL, Boyd RL. Apical root resorption in orthodontically treated adults. *Am J Orthod Dentofacial Orthop* 1996;110(3):311-20.
50. Mirabella AD, Artun J. Prevalence and severity of apical root resorption of maxillary anterior teeth in adult orthodontic patients. *Eur J Orthod.* 1995;17(2):93-9.
51. Hendrix I, Carels C, Kuijpers-Jagtman AM, Van 'T Hof M. A radiographic study of posterior apical root resorption in orthodontic patients. *Am J Orthod Dentofacial Orthop.* 1994;105(4):345-9.
52. Harris EF, Robinson QC, Woods MA. An analysis of causes of apical root resorption in patients not treated orthodontically. *Quintessence Int.* 1993;24(6):417-28.
53. Sameshima GT, Sinclair PM. Characteristics of patients with severe root resorption. *Orthod Craniofacial Res.* 2004;7(2):108-14.
54. Owman-Moll P, Kurol J, Lundgren D. Repair of orthodontically induced root resorption in adolescents. *Angle Orthod.* 1995;65(6): 403-8.
55. Owman-Moll P, Kurol J. The early reparative process of orthodontically induced root resorption in adolescents: location and type of tissue. *Eur J Orthod.* 1998;20(6):727-32.
56. Chan EKM, Darendelilar MA, Petocz P, Jones AS. A new method for volumetric measurement of orthodontically induced root resorption craters. *Eur J Oral Sci.* 2004;112(2):134-39.

57. Taner T, Ciger S, Sencift Y. Evaluation of apical root resorption following extraction therapy in subjects with Class I and Class II malocclusions. *Eur J Orthod.* 1999;21(5):491-6.

58. Owman-Moll P, Kurol J, Lundgren D. Continuous versus interrupted continuous orthodontic force related to early tooth movement and root resorption. *Angle Orthod.* 1995;65(6):395-402.